

“Effect of Asymmetric Premolar Extractions on Smile Aesthetics in A Patient With Severe Crowding” – A Case Report

Dr. Bhushan Jawale¹, Dr. Lishoy Rodrigues^{2*}, Dr. Tushar Patil³, Dr. Vijay Naik⁴, Dr. Amit Nehete⁵, Dr. Sameer Narkhede⁶

¹Dr. Bhushan Jawale, Professor, Dept of Orthodontics and Dentofacial Orthopedics, Sinhgad Dental College and Hospital, Sinhgad, Pune, Maharashtra, India

²Dr. Lishoy Rodrigues, PG Student, Dept of Orthodontics and Dentofacial Orthopedics, Sinhgad Dental College and Hospital, Sinhgad, Pune, Maharashtra, India

³Dr. Tushar Patil, Professor and HOD, Dept of Orthodontics and Dentofacial Orthopedics, Shri Yashwanthrao Chavan Dental College and Hospital, Ahmednagar, Maharashtra, India

⁴Dr. Vijay Naik, Professor and HOD, Dept of Orthodontics and Dentofacial Orthopedics, Maratha Mandal Dental College and Hospital, Belgaum, Karnataka, India

⁵Dr. Amit Nehete, Professor, Dept of Orthodontics and Dentofacial Orthopedics, MGV Dental College and Hospital, Sangli, Maharashtra, India

⁶Dr. Sameer Narkhede, Professor, Dept of Orthodontics and Dentofacial Orthopedics, Prof. DY Patil Dental College and Hospital, Navi Mumbai, Maharashtra, India

*Corresponding Author

Dr. Lishoy Rodrigues

Article History: | Received: 25.03.2021 | Accepted: 10.05.2021 | Published: 16.05.2021 |

Abstract: This case report evaluates the management of crowding in a female patient having a Class I malocclusion with the help of conventional fixed appliance mechano-therapy. The case required extraction of 3 premolars for correction of the proclined, forwardly placed and crowded upper and lower anterior teeth. Clinical and cephalometric evaluation revealed Class I skeletal pattern and clinical examination revealed presence of an orthognathic facial profile, an average to vertical growth pattern, increased overjet and average overbite, crowding in maxillary and mandibular anterior region, potentially incompetent lips, increased lip fullness and lip strain, a gummy smile with an unaesthetic flat smile arc and increased buccal corridor spaces. Following fixed orthodontic treatment by removal of 3 premolars and with retraction of anterior segment, a marked improvement in patient's smile, facial profile and occlusion was achieved and there was a remarkable increase in the patient's confidence and quality of life. The profile changes and treatment results were demonstrated with proper case selection and good patient cooperation with fixed appliance therapy.

Keywords: Asymmetric extractions, Gummy smile, Smile Aesthetics, Severe crowding, Fixed Orthodontic Mechanotherapy, Class I malocclusion, flat smile arc, Leptoprosopic facial form, Aesthetic Improvement, 3 Premolar Extractions, Orthodontic Camouflage, Unaesthetic smile, Therapeutic Extractions.

Copyright © 2021 The Author(s): This is an open-access article distributed under the terms of the Creative Commons Attribution **4.0 International License (CC BY-NC 4.0)** which permits unrestricted use, distribution, and reproduction in any medium for non-commercial use provided the original author and source are credited.

INTRODUCTION

In adolescents, tooth movement is affected by growth while in adults we deal strictly with tooth movement alone. In addition, orthodontic treatment in the adults is often based on symptoms detected by the patient while in adolescents; it is based more often on signs detected by practitioners or parents. Of equal significance is the fact that the adolescents seeks treatment more often for esthetic reasons and hence is likely to have unreasonable expectations about the

outcome of the treatment, is less adaptable to the appliance and is uncompromising in his appraisal of the treatment results. Fixed Appliance treatment can significantly alter and improve facial appearance in addition to correcting irregularity of the teeth. Facial Esthetics has been in increasing demand in today's century. Nowadays, patients with the slightest misalignment of teeth demand Orthodontic treatment to get it corrected and improve their smile and facial profile. Fixed Appliance treatment can significantly alter and improve facial appearance in addition to

Citation: Bhushan Jawale *et al* (2021). “Effect of Asymmetric Premolar Extractions on Smile Aesthetics in A Patient With Severe Crowding” – A Case Report, *SAR J Dent Oral Surg Med*, 2(3), 36-43.

correcting irregularity of the teeth [1]. The number of patients seeking orthodontic treatment has increased significantly [1,19, 26]. In Today's times, Fixed Appliance treatment can significantly alter and improve facial appearance in addition to correcting irregularity of the teeth. Class I malocclusion is the most prevalent followed by Class II and Class III malocclusion [2-3, 14-15]. Over the last few decades, there has been an increase in the awareness about orthodontic treatment which has led to more and more adolescents, especially girls demanding high quality treatment in the shortest possible time with increased efficiency and reduced costs [4, 16-18]. There are many ways to treat Class I malocclusions, according to the characteristics associated with the problem, such as antero-posterior discrepancy, age, and patient compliance [5-6, 20]. The indications for extractions in orthodontic practice have historically been controversial [7-9, 21]. On the other hand, correction of Class I malocclusions in growing patients, with subsequent dental camouflage to mask the skeletal discrepancy, can involve either retraction by non-extraction means simply by utilizing the available spaces or by extractions of premolars [10-11]. Lack of crowding or cephalometric discrepancy in the mandibular arch is an indication of 2 premolar extraction [12-13, 22-25]. Fortunately, in some instances satisfactory results with an exceptional degree of correction can be achieved without extraction of permanent premolars. This case presents the correction of crowding with a Class I malocclusion in an adolescent female patient with proclined maxillary and mandibular anterior teeth, merely simply by executing extraction of 3 premolars followed by fixed appliance therapy using conventional MBT fixed appliance mechanotherapy. The Extraction protocol shown in this case is indicative of how an unesthetic smile can be converted into a pleasant one by routine fixed Orthodontic treatment with extraction of 3 premolars followed by retraction and closure of spaces.

CASE REPORT

Extra-Oral Examination

A 16 year old female patient presented with the chief complaint of irregularly placed upper and lower front teeth and excessive show of upper gums. On Extra-oral examination, the patient had an orthognathic facial profile, grossly symmetrical face on both sides, a Leptoprosopic facial form, Dolicocephalic head form and average width of nose and mouth, potentially incompetent lips with increased lip strain and increased upper and lower labial fullness. The patient had no relevant prenatal, natal, postnatal history, history of

habits, medical or a family history. On Smiling, there was presence of crowding in the maxillary anterior region and a gummy smile with an unaesthetic flat smile arc and increased buccal corridor spaces. The patient was very dissatisfied with her smile.

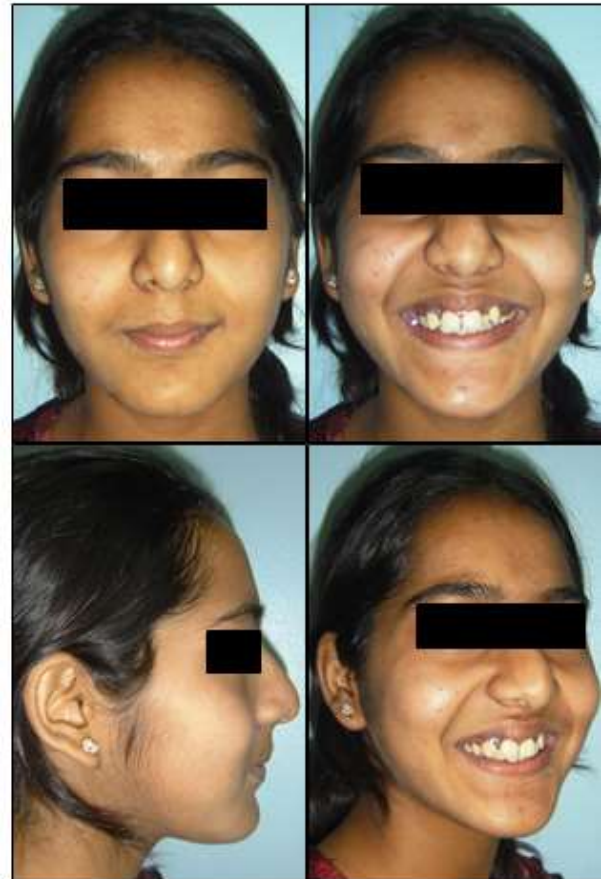

Fig-1: Pre treatment extra oral photographs

Intra-Oral Examination

Intraoral examination on frontal view showed presence of non-congruent upper and lower dental midlines with lower dental midline shifted to the left by 2mm. There was presence of crowding in the maxillary and mandibular anterior region with rotated anterior teeth and presence of in-standing lateral incisors. On lateral view the patient showed presence of Class II Division 1 incisor relationship, an End-on canine relationship and a Class I molar relationship bilaterally with an increased overjet of 4mm and proclined and forwardly placed upper and lower anterior teeth. The upper and lower arch showed presence of a "U" shaped arch form.

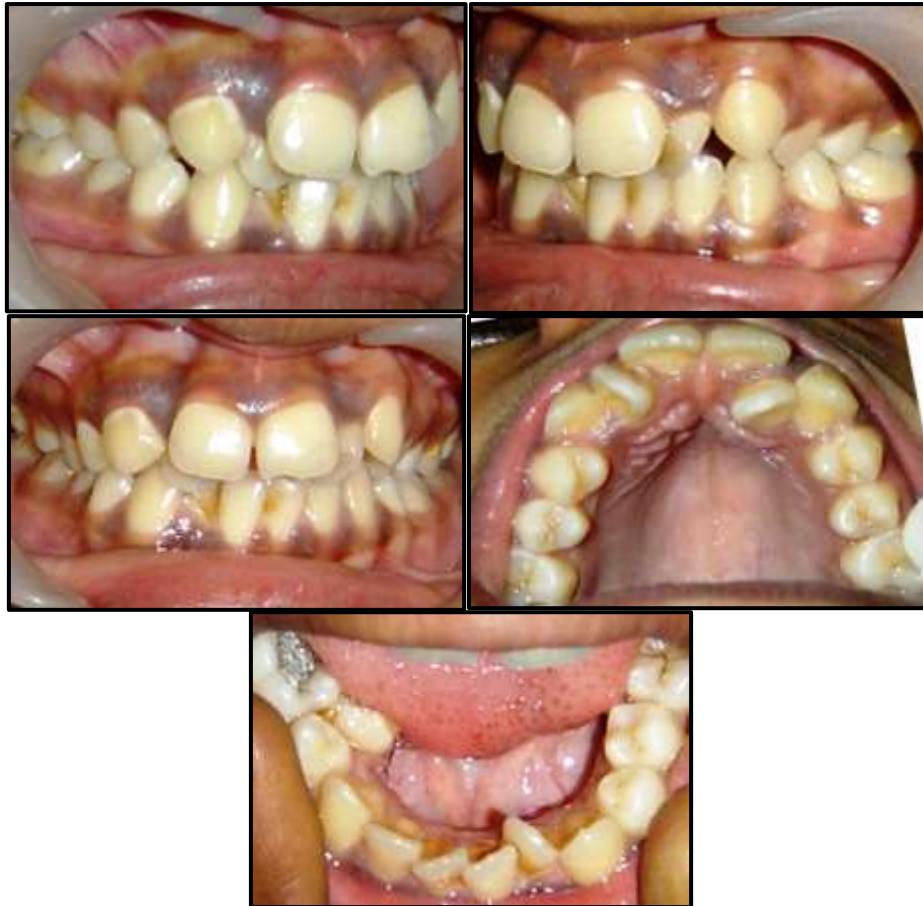


Fig-2: Pre treatment intra oral photographs

Table-1: Pre treatment cephalometric readings

| PARAMETERS | PRE- TREATMENT |
|--------------------|----------------|
| SNA | 81° |
| SNB | 79° |
| ANB | 2° |
| WITS | 1mm |
| MAX. LENGTH | 94mm |
| MAN. LENGTH | 108mm |
| IMPA | 99° |
| NASOLABIAL ANGLE | 95° |
| U1 TO NA DEGREES | 29° |
| U1 TO NA mm | 4mm |
| L1 TO NB DEGREES | 27° |
| L1 TO NB mm | 4mm |
| U1/L1 ANGLE | 121° |
| FMA | 28° |
| Y AXIS | 72° |
| L1 TO A-POG | 3mm |
| CONVEXITY AT PT. A | 1mm |
| LOWER LIP- E PLANE | 2mm |
| N-PERP TO PT A | 1mm |
| N-PERP TO POG | -1mm |
| CHIN THICKNESS | 12mm |

DIAGNOSIS

This 16 year old female patient was diagnosed with a Class II malocclusion on a Class I Skeletal base with an average to vertical growth pattern, proclined

upper and lower incisors, increased overjet, crowding in upper and lower anterior region with non-coincident dental midlines and rotated teeth, potentially incompetent lips with increased lip fullness and

increased lip strain, gummy smile, non-consonant flat smile arc and increased buccal corridor spaces.

List of Problems

1. Crowding in maxillary and mandibular anterior region
2. Proclined maxillary and mandibular dentition
3. Non coincident dental midlines
4. Increased Overjet
5. Rotated teeth
6. Gummy smile
7. Increased buccal corridor spaces
8. Potentially incompetent lips
9. Increased lip strain
10. Flat smile arc

Treatment Objectives

1. To correct crowding in maxillary and mandibular anterior teeth
2. To correct proclined maxillary and mandibular anterior dentition
3. To correct the non-coincident dental midlines
4. To correct the increased overjet
5. To correct the rotated teeth
6. To correct the existing gummy smile
7. To correct the unaesthetic increased buccal corridor spaces
8. To improve the lip competency
9. To decrease the lip strain
10. To correct the smile arc
11. To achieve a Class I incisor and canine relationship
12. To achieve a pleasing smile and a pleasing profile

Treatment Plan

- Extraction of 14, 24 and 34 with banding, bonding and fabrication of trans-palatal arch in the maxilla.
- Fixed appliance therapy with MBT 0.022 inch bracket slot.
- Initial leveling and alignment with 0.012", 0.014", 0.016", 0.018", 0.020" Niti archwires following sequence A of MBT.
- Retraction and closure of spaces by use of 0.019" x 0.025" rectangular NiTi followed by 0.019" x 0.025" rectangular stainless steel wires.
- Group A anchorage in the upper arch bilaterally and in the lower right quadrant.
- Final finishing and detailing with 0.014" round stainless steel wires.
- Retention by means of Hawley's retainers along with lingual bonded retainers in the upper and lower arch.

Treatment Progress

Complete bonding & banding in both maxillary and mandibular arch was done, using MBT-0.022X0.028"slot. Initially a 0.012" NiTi wire was used which was followed by 0.014, 0.016", 0.018", 0.020" Niti archwires following sequence A of MBT. After 6 months of alignment and leveling NiTi round wires were discontinued. Retraction and closure of existing

spaces was then started by use of 0.019" x 0.025" rectangular NiTi followed by 0.019" x 0.025" rectangular stainless steel wires. Reverse curve of spee in the lower arch and exaggerated curve of spee in the upper arch was incorporated in the heavy archwires to prevent the excessive bite deepening during retraction process and also to correct the already existing gummy smile. Anchorage was conserved in the upper and lower arch with the help of Group A anchorage. Retraction and closure of existing spaces was done with the help of Elastomeric chains delivering light continuous forces and replaced after every 4 weeks due to force decay and reduction in its activity. Retraction with the help of E-chains enabled getting the incisors and canines from Class II and an End on relationship respectively to a Class I incisor and canine relationship. Thus an ideal overjet and overbite was achieved at the end of the treatment. As asymmetric extractions were done, the molars had to be ended in a Class I on the left side and a Class II on the right side for the purpose of stability. Finally light settling elastics were given with rectangular steel wires in lower arch and 0.012" light NiTi wire in upper arch for settling, finishing, detailing and proper intercuspation. The upper and lower anterior proclination was corrected with an ideal occlusion at the end of the fixed appliance therapy. The unaesthetic looking wide buccal corridor spaces improved significantly at the end of treatment, thus improving the smile even further. There was improvement in occlusion, smile arc and profile at the end of the treatment and the patient's chief complaint of crowding and gummy smile was addressed.

DISCUSSION

Fixed Appliance treatment can significantly alter and improve facial appearance in addition to correcting irregularity of the teeth. Facial Esthetics has been in increasing demand in today's century. Nowadays, patients with the slightest misalignment of teeth demand Orthodontic treatment to get it corrected and improve their smile and facial profile. Fixed Appliance treatment can significantly alter and improve facial appearance in addition to correcting irregularity of the teeth. Treatment of maxillary and mandibular crowding with extraction of 3 premolars in an adolescent patient is challenging. A well-chosen individualized treatment plan, undertaken with sound biomechanical principles and appropriate control of orthodontic mechanics to execute the plan is the surest way to achieve predictable results with minimal side effects. Class II malocclusion might have any number of a combination of the skeletal and dental components. Hence, identifying and understanding the etiology and expression of Class II malocclusion and identifying differential diagnosis is helpful for its correction. The patient's chief complaint was irregularly placed upper and lower front teeth and excessive show of upper gums and sought treatment for the same. The selection of orthodontic fixed appliances is dependent upon several factors which can be categorized into patient factors,

such as age and compliance, and clinical factors, such as preference/familiarity and laboratory facilities. The most important point to be highlighted here is the decision to extract 3 premolars. After analyzing the case thoroughly and reading all pretreatment cephalometric parameters along with evaluating the patients profile clinically, a decision was made of proceeding with the treatment by extracting 3 premolars as the patient presented with severe maxillary and mandibular proclination with crowding and gummy smile, hence the case could not be managed without extractions. However we sought no need for extraction of premolar of the lower right quadrant as extraction of just 3 premolars would suffice to accomplish all pre-treatment goals. There was a significant decrease in the lip strain

and lip fullness with increased competency of lips. Crowding was unraveled, an ideal overjet and overbite was achieved, upper and lower dental midlines were coincident, smile arc was consonant with minimal buccal corridor spaces and pre-treatment gummy smile was corrected. Successful results were obtained after the fixed appliance therapy within a stipulated period of time. The overall treatment time was 17 months. After this active treatment phase, the profile of this 16 year old female patient improved significantly as seen in the post treatment Extra-oral photographs. Hawley’s retainers were then delivered to the patient along with fixed lingual bonded retainers in upper and lower arch. Patient was very happy and satisfied with the results of the treatment

Table-2: Post-treatment cephalometric readings

| PARAMETERS | POST - TREATMENT |
|--------------------|------------------|
| SNA | 81° |
| SNB | 79° |
| ANB | 2° |
| WITS | 0mm |
| MAX. LENGTH | 92mm |
| MAN. LENGTH | 108mm |
| IMPA | 93° |
| NASOLABIAL ANGLE | 107° |
| U1 TO NA DEGREES | 23° |
| U1 TO NA mm | 1mm |
| L1 TO NB DEGREES | 22° |
| L1 TO NB mm | 1mm |
| U1/L1 ANGLE | 132° |
| FMA | 27° |
| Y AXIS | 72° |
| L1 TO A-POG | 1mm |
| CONVEXITY AT PT. A | 0mm |
| LOWER LIP- E PLANE | 0mm |
| N-PERP TO PT A | 0mm |
| N-PERP TO POG | -1mm |
| CHIN THICKNESS | 12mm |

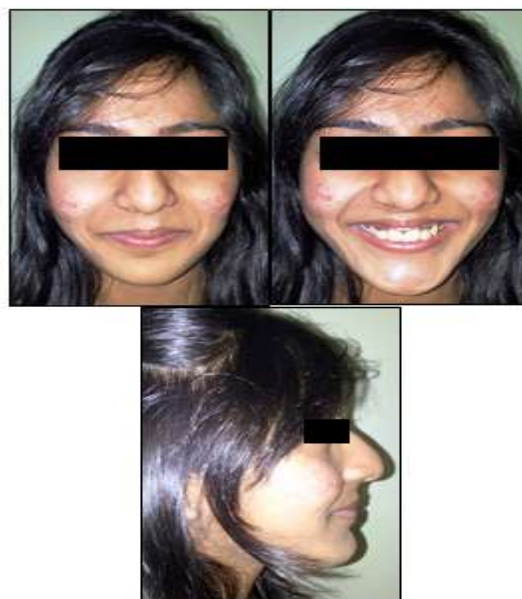

Fig-3: Post treatment extra oral photographs

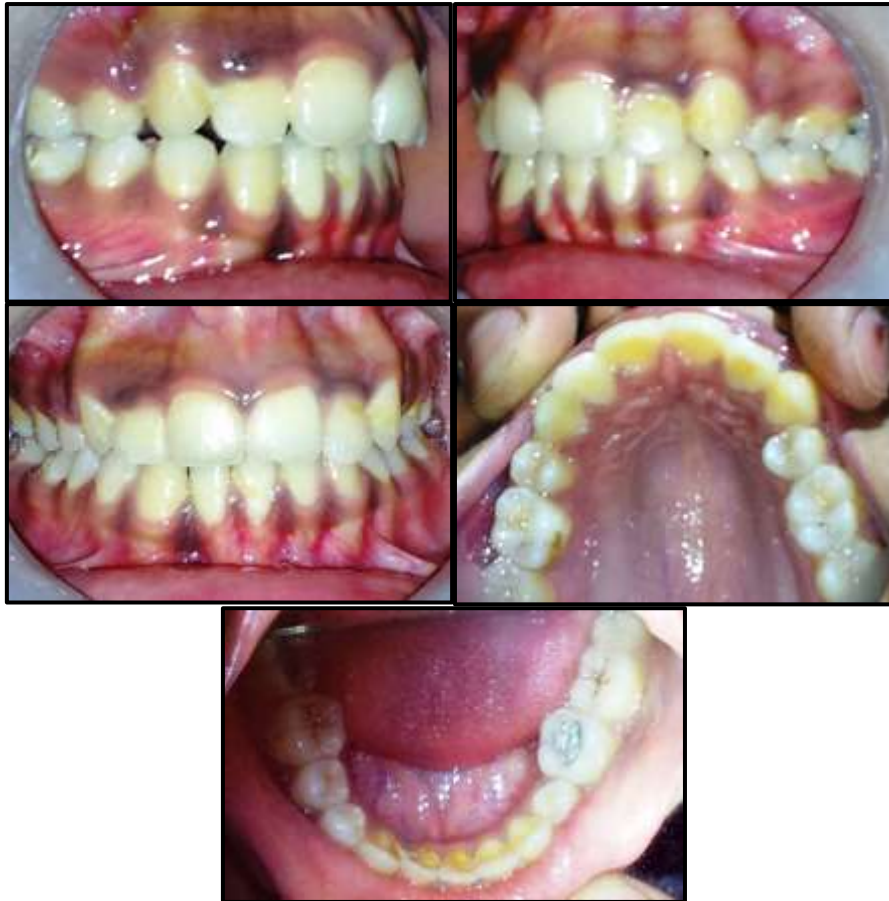

Fig-4: Post treatment intra oral photographs

Table-3: Comparison of pre and post treatment cephalometric readings

| PARAMETERS | PRE- TREATMENT | POST-TREATMENT |
|--------------------|----------------|----------------|
| SNA | 81° | 81° |
| SNB | 79° | 79° |
| ANB | 2° | 2° |
| WITS | 1mm | 0mm |
| MAX. LENGTH | 94mm | 92mm |
| MAN. LENGTH | 108mm | 108mm |
| IMPA | 99° | 93° |
| NASOLABIAL ANGLE | 95° | 107° |
| U1 TO NA DEGREES | 29° | 23° |
| U1 TO NA mm | 4mm | 1mm |
| L1 TO NB DEGREES | 27° | 22° |
| L1 TO NB mm | 4mm | 1mm |
| U1/L1 ANGLE | 121° | 132° |
| FMA | 28° | 27° |
| Y AXIS | 72° | 72° |
| L1 TO A-POG | 3mm | 1mm |
| CONVEXITY AT PT. A | 1mm | 0mm |
| LOWER LIP- E PLANE | 2mm | 0mm |
| N-PERP TO PT A | 1mm | 0mm |
| N-PERP TO POG | -1mm | -1mm |
| CHIN THICKNESS | 12mm | 12mm |

CONCLUSION

This case report illustrates how a case with crowding and gummy smile can be managed with Extraction of 3 premolars by means of appropriate use

of conventional MBT prescription along with efficient conservation of anchorage at the same time. The planned goals set in the pre-treatment plan were successfully attained. Treatment of the proclined and

forwardly placed upper and lower anterior teeth included the retraction of maxillary and mandibular incisors with a resultant decrease in soft tissue procumbency and facial convexity. The maxillary and mandibular teeth were found to be esthetically satisfactory in the line of occlusion. Patient had an improved smile and profile. The correction of the malocclusion was achieved, with a significant improvement in the patient aesthetics and self-esteem. The patient was very satisfied with the result of the treatment.

REFERENCES

1. Jawale Bhushan, Rodrigues Lishoy, Vora Ketan and Umalkar Devika. (2019). "Braces guarantee happiness and self confidence – a questionnaire based study", *International Journal of Current Research*, 11, (07), 5304-5307.
2. Hossain, M. Z., Haque, S., Yasmin, S., Haque, A., & Bahar, R. (1994). Prevalence of malocclusion and treatment facilities at Dhaka Dental College and Hospital. *J Oral Health*, 1(1).
3. Ahmed, N., & Chowdhury, K. (1996). Prevalence of malocclusion and its etiological factors, *J Oral Health*, 2(2), 12.
4. Khan, R. S., & Horrocks, E. N. (1991). A study of adult orthodontic patients and their treatment, *British journal of orthodontics*, 18(3), 183-194.
5. Salzman JA. (1966). *Practice of orthodontics*, Philadelphia: J. B. Lippincott Company; p. 701-24.
6. McNamara, J.A. (1981). Components of Class II malocclusion in children 8 10 years of age, *Angle Orthod*, 51:177-202.
7. Case C S. (1964). The question of extraction in orthodontia, *American Journal of Orthodontics*, 50: 660–691.
8. Case C S. (1964). The extraction debate of 1911 by Case, Dewey, and Cryer. Discussion of Case: the question of extraction in orthodontia. *American Journal of Orthodontics*, 50: 900–912.
9. Tweed C. (1944). Indications for the extraction of teeth in orthodontic procedure. *American Journal of Orthodontics* 30: 405–428;
10. Cleall JF, Begole EA. (1982). Diagnosis and treatment of Class II Division 2 malocclusion. *Angle Orthod* 52:38-60;.S
11. Strang RHW. (1957). *Tratado de ortodoncia*. Buenos Aires: Editorial Bibliográfica Argentina, p. 560-70, 657- 71
12. Bishara SE, Cummins DM, Jakobsen JR, Zaher AR. (1995). Dentofacial and soft tissue changes in Class II, Division 1 cases treated with and without extractions, *Am J Orthod Dentofacial Orthop*, 107:28-37; Rock WP.
13. Rock, W. P. (1990). Treatment of Class II malocclusions with removable appliances. Part 4. Class II division 2 treatment. *British dental journal*, 168(7), 298-302.
14. Bhushan Jawale, D., Rodrigues, L., Keluskar, K. M., Jatti, R., Belludi, A., & Hattarki, R. (2020). Treatment of a growing male having a recessive mandible with removable myofunctional appliance therapy followed by fixed orthodontic treatment: A.
15. Jawale B, Rodrigues L, Garde JB, Belludi A, Patil A, Palande P. (2020). Interdisciplinary collaboration of orthodontics and oral and maxillofacial surgery for the correction of severe class III skeletal pattern in an adult male with an hapsburg jaw-A case report on surgical orthodontics. *IP Indian Journal of Orthodontics and Dentofacial Research*, 15;6(3):149-56.
16. Lishoy R, Priyal R, Jamenis SC, Jawale B, Mahajan N. (2020). A survey to assess the knowledge and attitude of adults from the age group of 18 to 35 Years towards comprehensive orthodontic treatment-A questionnaire based study on adult orthodontics, *IP Indian Journal of Orthodontics and Dentofacial Research*, 15;6(4):255-63.
17. Bhushan Jawale, D., Rodrigues, L., Naik, V., Kerudi, V., Chaudhary, A., & Nehete, A. (2020). Management of a non growing adult borderline extraction case of a patient having a Class II Division 1 malocclusion by non extraction protocol for aesthetic improvement: A case report on adult orthodontics.
18. Jawale B, Lishoy R, Belludi A, Pharande A, Hattarki R, Prasad L. (2020). Correction of bimaxillary dentoalveolar protrusion in a growing male with class I malocclusion by extraction of premolars and profile improvement using conventional fixed orthodontic treatment-A case report on orthodontic camouflage. *IP Indian Journal of Orthodontics and Dentofacial Research*, 15;6(3):157-62.
19. Rodrigues L, Jawale B, Kadam A, Rajani P. (2020). Single phase correction of tongue thrust habit alongside fixed orthodontic treatment for closure of spaced dentition and midline diastema in a male patient with class I malocclusion without need for a two phase appliance therapy-A case report. *IP Indian Journal of Orthodontics and Dentofacial Research*, 15;6(3):163-9.
20. Rodrigues L, Jamenis SC, Jawale B, Patil R, Sadhunavar T. (2020). An assessment of knowledge and application of lingual orthodontics among orthodontists in their routine clinical practice. *IP Journal of Surgery and Allied Sciences*, 15;2(3):89-94.
21. Rodrigues L, Jamenis SC, Jawale B, Patil S, Garcha V. (2021). A questionnaire study to assess and evaluate the common gingival problems faced by patients undergoing fixed orthodontic treatment, *IP International Journal of Maxillofacial Imaging*, Jan 15;6(4):101-7.
22. Jawale B, Rodrigues L, Shinde K, Kangane S, Hattarki R, Mhatre S. (2020). Rhinoplasty, septoplasty and genioplasty with fixed orthodontic

- mechanotherapy for non-surgical correction of a patient with “Long face syndrome” Having a class III malocclusion on a class II skeletal jaw base-A case report. *IP Indian Journal of Orthodontics and Dentofacial Research*, 15;6(3):170-6.
23. Jawale B, Rodrigues L, Keluskar KM, Patil S, Belludi A, Patil A. (2020). Forsus fixed functional appliance therapy for dentoalveolar and profile correction-A case report, *IP Indian Journal of Orthodontics and Dentofacial Research*, 15;6(4):264-70.
24. Rashi, L., Priyal, R., Marisca, P., & Aljeeta, K. An assessment of common concerns of 2nd year post graduate students pursuing MDS In orthodontics and dentofacial orthopedics, due to the COVID-19 lockdown..
25. Jawale D.B., Rodrigues D.L., D.B.K., D.A.N., D.N.K., D.R.K.S. (2021). “CONVENTIONAL MBT MECHANOTHERAPY FOR CORRECTION OF AN UNAESTHETIC SMILE WITH A MIDLINE DIASTEMA AND SPACED DENTITION” – A CASE REPORT, *Advance Research Journal of medical and clinical Science*, 477-483.