

Original Research Article

Evaluation of Presurgical / Postraumatic Neurosensory Changes in the Management of Mandibular Fractures

Dr. Shrinivas B¹, Dr. Vinayak G. Naik^{2*}, Dr. Kirthi Kumar Rai³, Dr. Gaurav Malik⁴

¹Dept. of Oral & Maxillofacial Surgery, Bapuji Dental College and Hospital, Davangere 577004 Karnataka, India

²Reader, Dept. of Oral & Maxillofacial Surgery, Bapuji Dental College & Hospital, P O Box #326, Davangere- 577004 Karnataka, India

³Dept of Oral & Maxillofacial Surgery, Bapuji Dental College and Hospital, Davangere 577004 Karnataka, India

⁴Dept. of Oral & Maxillofacial Surgery, Bapuji Dental College and Hospital, Davangere 577004 Karnataka, India

***Corresponding Author**

Dr. Vinayak G. Naik

Article History

Received: 17.03.2020

Accepted: 25.03.2020

Published: 17.11.2020

Abstract: Background and Purpose: Fractures of mandible frequently result in inferior alveolar nerve (IAN) injury and altered neurosensory function. This may be due to primary injury which lies in the line of fracture or a secondary insult due to manipulation at the time of fixation of the fracture. The purpose of this study is to measure post-injury/pre-treatment and immediate postoperative IAN sensory changes during the management of mandibular fractures and to identify risk factors for adverse perioperative IAN neurosensory changes. **Materials and Methods:** This study was conducted on the patients admitted in the Department of Oral and Maxillofacial Surgery, Bapuji Dental College and Hospital, Davangere. Fracture location was divided into two categories as Fracture location 1 (L1) which was between the lingula and mental foramen which place the IAN at direct risk for injury & Fracture location 2 (L2) included fractures distal to the mental foramen. In these cases, the IAN is out of the bone and hence at risk for injury indirectly (i.e., via soft tissue trauma). Treatment was rendered in a non-randomized manner by the surgeon. To assess neurosensory function, protocol described by Zuniga and Essick will be used. All the required parameters were measured & recorded pre-operatively & post-operatively. **Results:** The results of the present study showed that fracture displacement of more than 4 mm at L1 site & excess manipulation of soft tissues at L2 site was associated with Significant Neurosensory Deficit. **Conclusion:** Identifying the factors associated with poor long term outcome of NSD would need a larger sample size and detailed documentation of the use of various diagnostic tools to arrive at a conclusive observation.

Keywords: Neurosensory Deficit; Mandibular Fractures; Neurosensory Function.

INTRODUCTION

The face, and in particular the oral and perioral regions, are among the areas with the highest density of peripheral receptors, presumably because of their remarkable importance in daily life. It is difficult to tolerate neurological disturbances in oral and maxillofacial areas compared to disturbances in other parts of the body [1].

Pain, temperature, touch, pressure and proprioception are transmitted centrally from the perioral structures via the inferior alveolar, lingual, infraorbital and mental nerves. Each of these sensations is carried out by different type of sensory receptors and nerve fibres, showing different susceptibility to injury and recovery [2].

Maxillofacial neurosensory deficiency may be caused by various surgical procedures such as tooth extraction, osteotomies, preprosthetic procedures, excision of tumors of cyst, surgery of TMJ, and surgical treatment of fracture and cleft lip/palate [3].

Clinical neurosensory testing is generally divided into two basic categories based upon the specific receptors stimulated through cutaneous contact, which are Mechanosensitive & Nociceptive [4-6].

Copyright © 2020 The Author(s): This is an open-access article distributed under the terms of the Creative Commons Attribution 4.0 International License (CC BY-NC 4.0) which permits unrestricted use, distribution, and reproduction in any medium for non-commercial use provided the original author and source are credited.

Mechanoeptive testing is further divided into subgroups: Two-point discrimination, Static light touch & Brush directional stroke tests. Nociceptive testing is further divided into: Pin-prick & Thermal discrimination (localization, sharp/blunt discrimination and dental vitality) tests [4-6].

Although restoration of anatomic form and function is the goal of trauma management, the documentation of neurosensory function has been a neglected area in maxillofacial trauma research. Fractures of the mandible frequently result in inferior alveolar nerve (IAN) injury and altered neurosensory function. This may be due to primary injury when IAN lies in the line of fracture or a secondary insult due to manipulation and fixation of the fracture [7-10].

If the follow-up examination carried out one year after surgery continued to reveal a sensory disturbance, this was defined as a permanent neurological deficit, since recovery of sensation is usually complete after one year. Neurosensory testing is designed to determine the degree of sensory disturbance, to monitor sensory recovery, and to point out whether or not surgical intervention may be indicated [11, 12]. The present study aimed at evaluating the incidence of neurosensory deficits in patients who have undergone surgical treatment for mandibular fractures and posttraumatic patients.

METHODOLOGY

We designed a prospective study using a total 60 sample derived from the series of patients with mandibular fractures evaluated and treated by, Department of Oral and maxillofacial surgery, Bapuji Dental College and Hospital, Davangere. Nov 2012 to May 2014. The Institutional Review Board approved the study. The aim of the study was to measure post-injury/pre-treatment and immediate post-operative IAN sensory changes during the management of mandibular fractures and to identify risk factors for adverse peri-operative IAN neurosensory changes. The inclusion criteria were the presence of a mandibular fracture located between the lingula and parasymphysis of the mandible, the availability of preoperative and postoperative panoramic radiographs and a level of mental status permitting an adequate neurosensory examination and the exclusion criteria were fractures proximal to lingual, lack of requisite imaging, incapable of completing an adequate neurosensory examination, inability to communicate patient (with sedated or intubated) and pan facial fractures.

The predictor variables were grouped into the following sets: demographic (age and gender), anatomic (fracture location and displacement), post injury/pre-treatment neurosensory status (normal or abnormal) and treatment (closed or open reduction). Fracture location was divided into two categories. Fracture location 1: was between the lingula and mental foramen. These fractures place the IAN at direct risk for injury. Fracture location 2: included fractures distal to the mental foramen. In these cases, the IAN is out of the bone and hence at risk for injury indirectly (i.e., via soft tissue trauma). Reduction and fixation of the fractures at either location may result in incremental IAN injury. Fracture displacement was categorized as 5 mm or less and greater than 5 mm. The panoramic radiographs were reviewed to determine degree of fracture displacement.

Based on the neurosensory examination, post injury /pre-treatment IAN neurosensory status was classified as being normal or abnormal. Patients with abnormal post-injury/pre-treatment IAN neurosensory examinations are considered to have primary IAN injuries. Patients with normal post injury/pre-treatment neurosensory examinations who are at risk for having IAN injury due to fracture treatment were considered as secondary IAN injury. Fracture treatment included were (i) Closed reduction (CR) and maxillomandibular fixation (MMF) or (ii) Open reduction and rigid internal fixation (ORIF). Treatment was rendered in a non-randomized manner by the surgeon and recorded. Patients treated for mandibular parasymphysis and angle fractures were examined for hypoesthesia in the region supplied by the inferior alveolar and the mental nerve.

Intraoperatively, the amount of displacement of fracture was noted in mm. To assess neurosensory function, protocol described by Zuniga and Essick was used. Clinical neurosensory tests were conducted by two point discrimination, static light touch, brush directional stroke, pin prick, thermal discrimination at pre and post operatively. (Fig. 1 & 2). In all groups, unoperated cutaneous areas on the contralateral side were chosen as control areas.

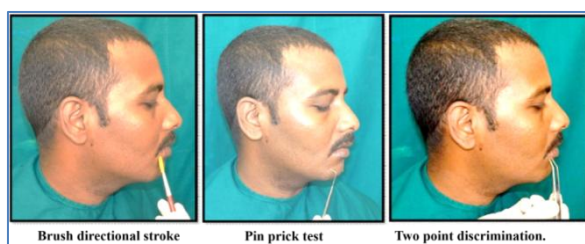

Fig-1: Brush directional stroke, pin prick test & 2 point discrimination test

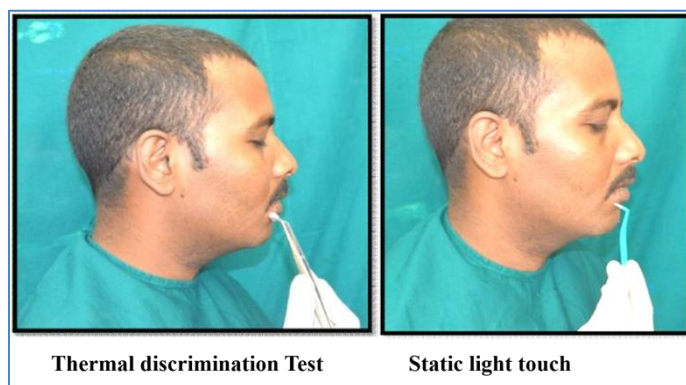


Fig-2: Thermal discrimination test & Static light touch test

All the neurosensory tests were performed in a room free from acoustic or visual stimuli. Before the applications, the patients were informed of them. The testing began after the patient closed his/her eyes and separated his lips comfortably. Each of the areas was tested three times, a correct response was considered as two out of three appropriate answers. The prospective study was conducted by evaluating the clinical details in the patient's records. Any preoperative/post traumatic nerve injury presented as hypoesthesia was noted. Postoperatively, the patient's records were checked for any persistent hypoesthesia. Results obtained were statistically analyzed by Mc Nemar's Chi square test to assess for any difference between the groups. A value of $p < 0.05$ was considered as statistically significant.

RESULTS

In this study a total of 60 patients who had underwent mandibular fractures treatment were subjects for neurological evaluation pre-operatively and post-operatively. The age distribution of the patients was between 17 -58 years with a mean age being 31.41 ± 11.04 years. The patients were predominantly male comprising 44 (73.33%) and females 16 (26.67%) of the total cases (Table 1).

Table-1: Distribution of study subjects in L1 & L2 fracture sites.

Fracture Site	Number of fractures	Mean Age \pm SD	Total Number of Males	Mean Age \pm SD	Total No of Females	Mean Age \pm SD
L1	29	31.41 ± 11.04	23	31.21 ± 10.62	6	32.16 ± 13.60
L2	31	31.70 ± 10.11	21	29.33 ± 07.35	10	36.70 ± 13.40

The location L1 comprises of those fractures was between the lingula and mental foramen. In our study there was injury to the L1 site in 48.33% of the cases while neurosensory score remained unchanged in 55% of the cases. In a total number of 29 (48.33%) cases, paraesthesia was present in 16 (55.17%) patients preoperatively and it was evident in 17 (58.62%) cases postoperatively. Therefore while comparing the results before and after treatment at L1, we got the P value of 0.796 which is non-significant. This was in accordance with previous studies. In our study NSD scores before treatment at L1 was 2.034 ± 1.051 and after treatment was 2.172 ± 2.55 yielded a P value of 0.585 which is non significant.

The location L2 comprises of those fractures distal to the mental foramen. Our study consisted of 31 (51.66%) cases of fractures at L2 site. Out of that 31 (51.66%) cases with a mean age \pm SD was 31.70 ± 10.11 , 21 (67.74%) were males with a mean age \pm SD of males was 29.33 ± 07.35 and 10 (32.25%) were females with a mean Age \pm SD was 32.16 ± 13.40 .

Level A test results showed a Total of 12 (38.70%) cases with no displacement and absence of paraesthesia before treatment, but 10 (32.25%) cases showed paraesthesia after treatment. Out of 12(38.70%) cases present with 1-2mm displacement, there were 1 (3.22%) cases of paraesthesia before treatment but later increased to 9 (75%) cases after treatment. Out of 5(16.12%) cases with 3-4mm displacement 1(20%) cases were presented with paraesthesia before treatment and 4(80%) cases after treatment respectively, in 2 (6.45%) cases with large displacement of more than 4mm displacement, all cases ended up with paraesthesia before treatment and post operative following period. Level B test results showed, 12(38.70%) cases were with no displacement and absence of paraesthesia before treatment but resulted in 2(6.45%) patients with paresthesia after treatment. Out of 12(38.70%) cases present with 1-2mm displacement, there were none of the cases had paraesthesia before treatment but later it was increased to 7(58.33%) cases after treatment. Out of 5 (16.12%) cases with 3-4mm displacement, none of the cases were presented with paraesthesia before treatment and 4 (80%) patients after the treatment, in Two cases with large displacement of more than 4mm displacement, One

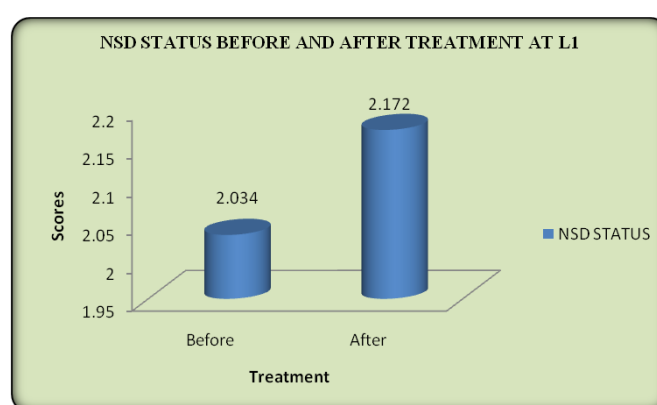
case were presented with paraesthesia before treatment and Two cases were presented following treatment. Level C test results showed a total of 12 (36.70%) cases which were with no displacement and absence of paraesthesia before and after the treatment. Out of 12 (36.70%) cases present with 1-2mm displacement, all of the cases had paraesthesia before and after treatment. Out of 5 (16.12%) cases with 3-4mm displacement 1(3.22%) case presented with paraesthesia before treatment and 1(3.22%) case after treatment. In large displacement of more than 4mm displacement none of the cases presented with paraesthesia before treatment though we saw an increased of 2 (6.45%) cases with paresthesia following treatment (Table 2, Graph 1 & 2).

The overall NSD scores before treatment at L2 was 1.225 ± 0.616 and after treatment was 2.387 ± 0.919 yielded a P value of 0.000 which is highly significant (Table 2)

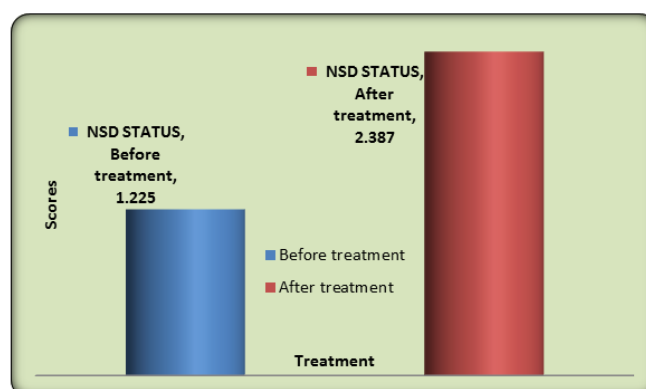
Table-2: Nsd Scores Before and After Treatment at L1 & L2

NSD STATUS	Before treatment	After treatment	Paired t test	P value	Significance
L1	2.034 ± 1.051	2.172 ± 1.255	0.583	0.565	NS
L2	1.225 ± 0.616	2.387 ± 0.919	6.670	0.000	HS

NS- Non Significant, HS- Highly Significant



Graph-1: Nsd Scores Before and After Treatment at L1



Graph-2: NSD Scores Before and After Treatment at L2

DISCUSSION

Fractures of the mandible frequently result in inferior alveolar nerve (IAN) injury and altered neurosensory function. This may be due to primary injury when the IAN lies in the line of fracture or a secondary insult due to manipulation and fixation of the fracture.³ Despite the large numbers of mandibular fractures treated by generations of oral and maxillofacial surgeons, there is a paucity of data documenting the natural history of IAN deficits associated with this injury and its management. In addition, there is little helpful information for the surgeon regarding prognosis for recovery of IAN neurosensory function. The studies that do exist use censored data and exhibit other methodological problems limiting their clinical value. To address this deficiency in the literature, the aim of our prospective study was to document the natural history of posttraumatic IAN injury and to identify risk factors associated with persistent neurosensory deficits [3].

The location L1 fractures reported paresthesia in 55.17% patients preoperatively and in 58.62% cases postoperatively with a p value of 0.796. This was in accordance with previous studies[2, 8, 25, 27]. Sensory disturbance in the mental skin region could be caused by damage to the nerve at the time of injury or, secondarily, by surgery. In most studies on rigid internal fixation, the incidences of postoperative sensory deficits have been seen to be between 0.9% to 34%, which is lower than the percentage observed in our study. One reason for the high incidence of sensory disturbance in our patients may have been the relatively large numbers of displaced body and angular fractures[2, 8, 25, 27].

The location L2 comprises of those fractures distal to the mental foramen. Our study consisted of 31 (51.66%) cases of fractures at L2 site. Level A test results showed a Total of 12 (38.70%) cases with no displacement and absence of paraesthesia before treatment, but 10 (32.25%) cases showed paraesthesia after treatment. Level B test results showed, 12(38.70%) cases were with no displacement and absence of paraesthesia before treatment but resulted in 2(06.45%) patients with paresthesia after treatment. Level C test results showed a total of 12 (36.70%) cases which were with no displacement and absence of paraesthesia before and after the treatment. At the start of the study, we thought that patients with fractures distal to the mental foramen would have a low risk for having an MN injury. However, we found that the MN injury was indeed more frequent (51.66%). This could be because the MN needs to be retracted/ dissected free to be able to allow appropriate fracture fixation, especially when two plate fixation was carried out. Typically, the nerve is isolated and a thin malleable retractor or a periosteal elevator is used to protect it during the plating process. Further, when the fracture line runs through or close to the mental foramen, it is not uncommon to place screws on either side of the nerve as it exits the mental foramen therefore this presents a situation where in the spinning drill could injure the nerve while drilling[20-27].

Another observation that may be clinically relevant when discussing treatment options with patients who have mandibular fractures with normal post injury/pre-treatment IAN/MN neurosensory examinations is that there exists a small risk of worsening of their IAN/MN neurosensory function after treatment, regardless of the degree of fracture displacement. There fore, in terms of setting patients' expectations, it may be valuable to inform patients that they may expect a change in their IAN neurosensory status after treatment[14-20, 22, 27].

Theoretically, the nerve can be involved in traction and/ or compression caused by manipulation of fragments during fracture reduction and stabilization. Extraction of a tooth from the line of fracture could also cause injury to the inferior alveolar nerve. In addition, a bicortical screw placed near the mandibular canal might irritate or damage the nerve. The postoperative sensory deficits observed in this study were possibly a result of the combined effects of all these factors. Paraesthesia is often observed in patients with edentulous and atrophic mandibles. A possible explanation for this correlation is that, due to lack of space, a screw is more likely to be placed in or close to the mandibular canal, thereby causing damage to the inferior alveolar nerve. Therefore, especially in atrophic mandibles, care must be taken to bend the plate to the correct shape and to place it exactly along the inferior border of the mandible. From this point of view, three-dimensional bendable reconstruction plates are probably preferable to other plates[2, 8, 11, 12, 14, 25, 27].

In our study we found that the fracture displacement played a very important role in development of paresthesia. The Radiological fracture displacement was in Location-1, < 4mm 21 (72.42%)patients and > 4mm 8 (27.58%)patients. In Location-2 < 4mm 29 (93.54%)patients and > 4mm 2 (6.45%)patients. In addition, the results suggest that along with fracture displacement, the operator manipulation were the key variables associated with injury to the IAN/MN during the initial postoperative phase of treatment adjusted for age and fracture location. Therefore we can conclude that patients with a fracture displaced greater than 4 mm had a 7-fold increased risk for IAN/MN injury after treatment compared with patients with fractures displaced 4 mm or less[18].

The strengths of our study are its prospective design and consistency of collection of IAN sensory data during the perioperative and postoperative period. The method of neurosensory measurement described by Zuniga & Essick, used is well documented, suitable for perioperative evaluations, and commonly used in follow-up studies of mandibular fracture treatment. Our study design has limitations because the nonrandomly selected treatment groups increases risk of selection bias. On the other hand, all the patients in this study did not significantly differ from various other studies when compared interms of their perioperative NSD changes[15-19].

As such, one could hypothesize that the postinjury/ pretreatment neurosensory examinations could vary with time duration as between injury and presentation. In this sample, the interval between injury and presentation for treatment ranged from 0 to 7 days. Over this time frame, there was not a statistically significant relationship between the interval between injury and presentation and the postinjury / pretreatment neurosensory scores. However, further studies are needed to establish such a possible relationship.

CONCLUSION

The results of this study suggest that for most patients the IAN neurosensory status is unchanged or improved after mandibular fracture treatment when compared with patient's post injury /pretreatment neurosensory status. In those case, where IAN neurosensory status deteriorates after treatment, the probable causes or risk factors are, fracture displacement and the method of surgical treatment. Few of the NSD outcomes would lack accuracy if the patients do not respond adequately to the various tests that need to be carried out at the time of assessment. Therefore identifying those factors associated with poor long term outcome of NSD would need large sample size and detailed documentation of the use of various diagnostic tools to arrive at a conclusive observation.

REFERENCES

1. Akal, Ü. K., Sayan, N. B., Aydoğan, S., & Yaman, Z. (2000). Evaluation of the neurosensory deficiencies of oral and maxillofacial region following surgery. *International journal of oral and maxillofacial surgery*, 29(5), 331-336.
2. Chow, H. T., & Teh, L. Y. (2000). Sensory impairment after resection of the mandible: a case report of 10 cases. *Journal of Oral and Maxillofacial Surgery*, 58(6), 629-635.
3. Halpern, L. R., Kaban, L. B., & Dodson, T. B. (2004). Perioperative neurosensory changes associated with treatment of mandibular fractures. *Journal of oral and maxillofacial surgery*, 62(5), 576-581.
4. Bochlogyros, P. N. (1985). A retrospective study of 1,521 mandibular fractures. *Journal of oral and maxillofacial surgery*, 43(8), 597-599.
5. Tu, H. K., & Tenhulzen, D. (1985). Compression osteosynthesis of mandibular fractures: A retrospective study. *Journal of oral and maxillofacial surgery*, 43(8), 585-589.
6. Theriot, B. A., Van Sickels, J. E., Triplett, R. G., & Nishioka, G. J. (1987). Intraosseous wire fixation versus rigid osseous fixation of mandibular fractures: a preliminary report. *Journal of oral and maxillofacial surgery*, 45(7), 577-582.
7. Dodson, T. B., Perrott, D. H., Kaban, L. B., & Gordon, N. C. (1990). Fixation of mandibular fractures: a comparative analysis of rigid internal fixation and standard fixation techniques. *Journal of oral and maxillofacial surgery*, 48(4), 362-366.
8. Iizuka, T., & Lindqvist, C. (1991). Sensory disturbances associated with rigid internal fixation of mandibular fractures. *Journal of oral and maxillofacial surgery*, 49(12), 1264-1268.
9. Iizuka, T., & Lindqvist, C. (1992). Rigid internal fixation of mandibular fractures: an analysis of 270 fractures treated using the AO/ASIF method. *International journal of oral and maxillofacial surgery*, 21(2), 65-69.
10. Tuovinen, V., Nørholt, S. E., Sindet-Pedersen, S., & Jensen, J. (1994). A retrospective analysis of 279 patients with isolated mandibular fractures treated with titanium miniplates. *Journal of oral and maxillofacial surgery*, 52(9), 931-935.
11. Jääskeläinen, S. K., Peltola, J. K., Forssell, K., & Vähätalo, K. (1995). Evaluating function of the inferior alveolar nerve with repeated nerve conduction tests during mandibular sagittal split osteotomy. *Journal of oral and maxillofacial surgery*, 53(3), 269-279.
12. Sandstedt, P., & Sörensen, S. (1995). Neurosensory disturbances of the trigeminal nerve: a long-term follow-up of traumatic injuries. *Journal of oral and maxillofacial surgery*, 53(5), 498-505.
13. Kallela, I., Iizuka, T., Laine, P., & Lindqvist, C. (1996). Lag-screw fixation of mandibular parasymphiseal and angle fractures. *Oral Surgery, Oral Medicine, Oral Pathology, Oral Radiology, and Endodontology*, 82(5), 510-516.
14. Zuniga, J. R., Meyer, R. A., Gregg, J. M., Miloro, M., & Davis, L. F. (1998). The accuracy of clinical neurosensory testing for nerve injury diagnosis. *Journal of oral and maxillofacial surgery*, 56(1), 2-8.
15. Lemke, R. R., Clark, G. M., Bays, R. A., Tiner, B. D., & Rugh, J. B. (1998). Effects of hypesthesia on oral behaviors of the orthognathic surgery patient. *Journal of oral and maxillofacial surgery*, 56(2), 153-157.
16. Marchena, J. M., Padwa, B. L., & Kaban, L. B. (1998). Sensory abnormalities associated with mandibular fractures: incidence and natural history. *Journal of oral and maxillofacial surgery*, 56(7), 822-825.
17. August, M., Marchena, J., Donady, J., & Kaban, L. (1998). Neurosensory deficit and functional impairment after sagittal ramus osteotomy: a long-term follow-up study. *Journal of oral and maxillofacial surgery*, 56(11), 1231-1235.
18. Griffiths, H., & Townend, J. (1999). Anesthesia of the inferior alveolar and lingual nerves as a complication of a fractured condylar process. *Journal of oral and maxillofacial surgery*, 57(1), 77-79.
19. Schultze-Mosgau, S., Erbe, M., Rudolph, D., Ott, R., & Neukam, F. W. (1999). Prospective study on post-traumatic and postoperative sensory disturbances of the inferior alveolar nerve and infraorbital nerve in mandibular and midfacial fractures. *Journal of Cranio-Maxillofacial Surgery*, 27(2), 86-93.
20. Moreno, J. C., Fernández, A., Ortiz, J. A., & Montalvo, J. J. (2000). Complication rates associated with different treatments for mandibular fractures. *Journal of Oral and maxillofacial Surgery*, 58(3), 273-280.
21. Fanibunda, K. (2000). Mandibular fracture resulting in displacement of the inferior alveolar nerve and allodynia. *Journal of oral and maxillofacial surgery*, 58(5), 557-559.

22. Ylikontiola, L., Kinnunen, J., & Oikarinen, K. (2000). Factors affecting neurosensory disturbance after mandibular bilateral sagittal split osteotomy. *Journal of oral and maxillofacial surgery*, 58(11), 1234-1239.
23. Lemke, R. R., Rugh, J. D., Van Sickels, J., Bays, R. A., & Clark, G. M. (2000). Neurosensory differences after wire and rigid fixation in patients with mandibular advancement. *Journal of oral and maxillofacial surgery*, 58(12), 1354-1359.
24. Gabrielli, M. A. C., Gabrielli, M. F. R., Marcantonio, E., & Hochuli-Vieira, E. (2003). Fixation of mandibular fractures with 2.0-mm miniplates: review of 191 cases. *Journal of oral and maxillofacial surgery*, 61(4), 430-436.
25. Al-Bishri, A., Rosenquist, J., & Sunzel, B. (2004). On neurosensory disturbance after sagittal split osteotomy. *Journal of oral and maxillofacial surgery*, 62(12), 1472-1476.
26. Wijbenga, J. G., Verlinden, C. R. A., Jansma, J., Becking, A. G., & Stegenga, B. (2009). Long-lasting neurosensory disturbance following advancement of the retrognathic mandible: distraction osteogenesis versus bilateral sagittal split osteotomy. *International journal of oral and maxillofacial surgery*, 38(7), 719-725.
27. Yazdani, J., Talesh, K. T., Motamedi, M. H. K., Khorshidi, R., Fekri, S., & Hajmohammadi, S. (2013). Mandibular angle fractures: comparison of one miniplate vs. two miniplates. *Trauma monthly*, 18(1), 17.