

Original Research Article

## Diagnosis of Temporomandibular Dysfunctions and Their Management

Dr Zenati Latifa<sup>1\*</sup>, Pr Ait Mehdi Mahdia<sup>1</sup>, Dr Chouakri S<sup>1</sup>, Pr Akerdichi<sup>1</sup>

<sup>1</sup>University Health of Science Algiers, Algeria

**\*Corresponding Author:** Dr Zenati Latifa  
University Health of Science Algiers, Algeria

### Article History

Received: 16.11.2025

Accepted: 07.01.2026

Published: 10.01.2026

**Abstract:** Temporomandibular disorders are dysfunctions of the temporomandibular joint, multifactorial etiology and multiple aspects, diagnosis and management are far from easy. The diagnostic approach must be rigorous and will have to follow a logical progression, the management when it requires us, a reflection on the therapeutic approach according to the clinical case treated. As part of this work, we will discuss the diagnostic approach to disc displacements as well as the different management options by shedding light on current therapies.

**Keywords:** Temporomandibular Dysfunction, Diagnosis, Mechanical Axiography, Disc Displacement, Occlusal Splint.

## INTRODUCTION

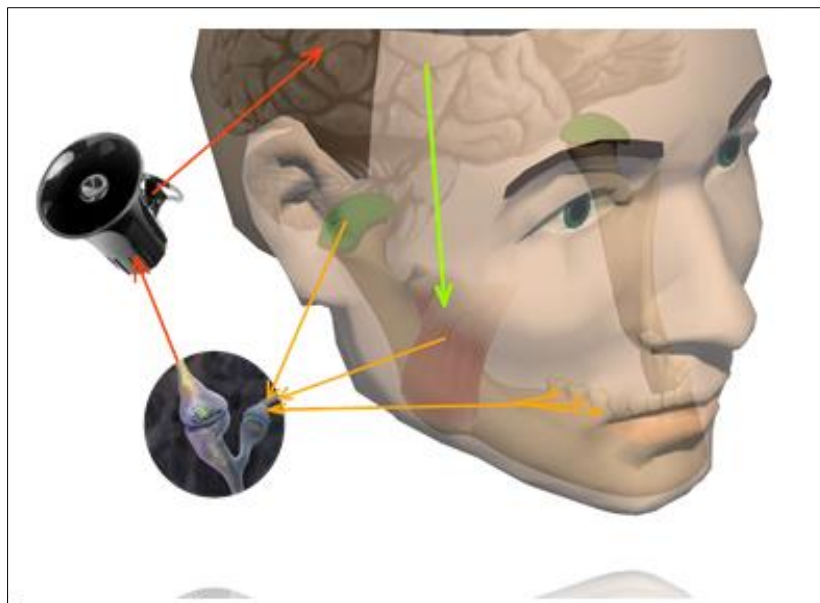
We receive daily patients who consult for pain of the oro-facial sphere within our dental prosthesis service. Differential diagnosis is played between the various dental pathologies, sinusitis, tinnitus, facial nephralgia, pain of postural origin and the different pathologies of the temporomandibular joint.

The management of each patient depends on the positive diagnosis that will dictate the appropriate treatment plan. The latter is sometimes difficult to be posed by the practitioner considering the complexity of the region (ocular, auricular, dental, sinus and postural), the diffusion and the intensity of the pain as well as its mode of appearance (spontaneous or provoked) [1].

The purpose of this article is to highlight our diagnostic approach and the deplorable means to come to know the mechanical axiography pursued by a therapeutic management of diagnosed dysfunction.

### Reminder on the Temporomandibular Joint:

The temporomandibular joint is a bi-condylar diarthrosis composed of two articular surfaces: the mandibular condyle, tubercle of the temporal bone between which is interposed the disc. This articulation works in synergy with the teeth and their periodontal, the muscles all under the control of the nervous system to ensure the proper functioning of the device manducator (Fig. 1).



**Fig. 1: Manducator system**

Temporomandibular Dysfunction or DTM is a multifactorial pathology with three dimensions: a biological dimension, a structural dimension and a psychosocial dimension.

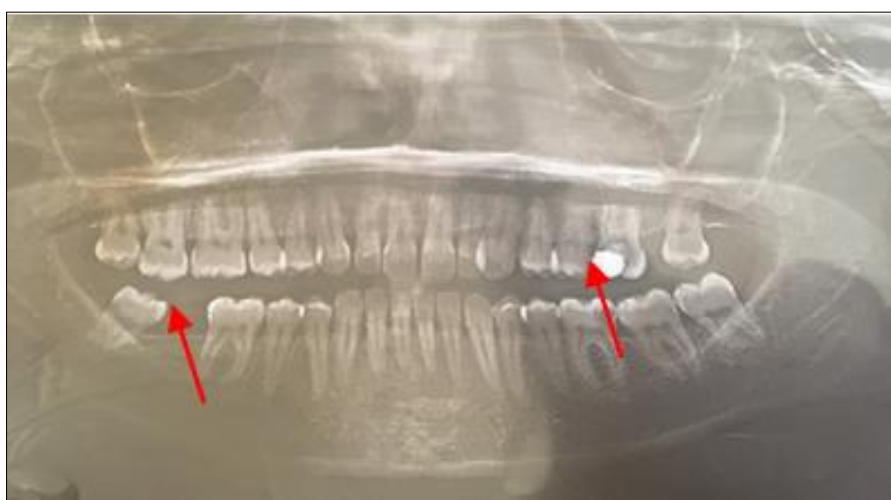The National Institute of Dental Craniofacial Research (NIDCR) estimates that between 5 and 12% of the world's population has at least one dysfunction of the manducatory apparatus. The diversity of the DTM can explain this prevalence in the population. According to the American Academy of Occlusal Pain (AAOP). TMDs are superimposed in two families: The muscular dysfunctions and joint dysfunctions, which must be added the emotional factor that will amplify the intensity of the pain [2].

How to conduct your diagnosis?

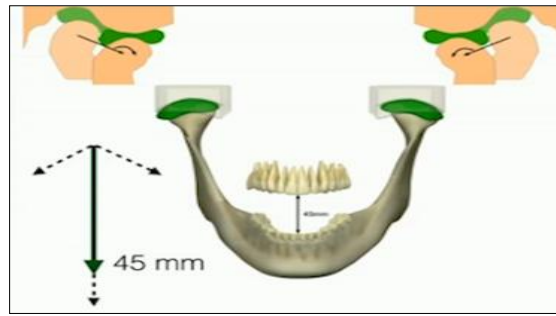
The diagnosis will begin with a consultation that will include a clinical card followed by an interview that will gather the subjective elements by creating a relationship of trust with the patient often stressed because of his problems.

An exobuccal clinical examination associated with muscular and articular palpations and endobuccal in search of a dental cause, the pan will ask systematically because it allows having an overview (Fig. 2).

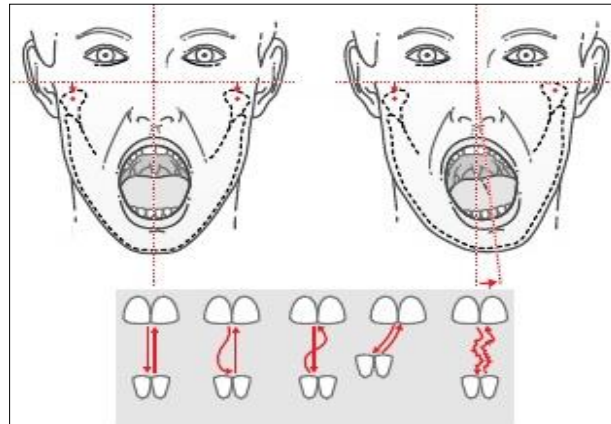
Pursued by an examination of the mandibular kinematics through passive and active movements of protrusion and diduction, opening and closing mouth thus drawing the diagram of FARRAR (Fig. 3, 4).



**Fig. 2: Panoramic X-ray reveals an overflow filling on the 16 and a mesial version of the 48 sources of prematurity and occlusal interferences**



**Fig. 3: Farrar diagram of normal amplitude**



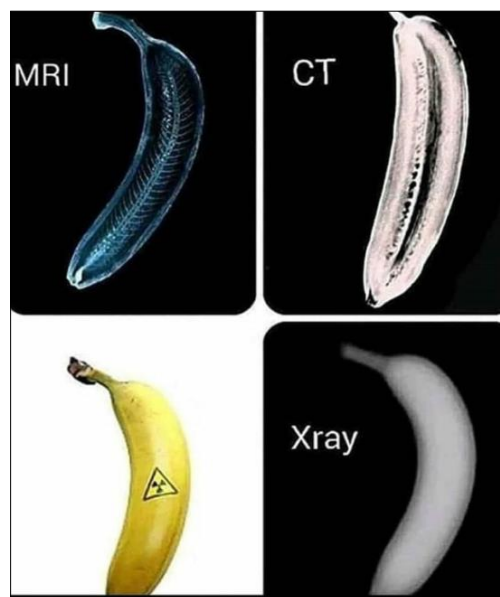
**Fig. 4: Different Farrar diagram according to the clinical case**

The main cardinal clinical signs are grouped under the term: ADB "Noise, Algia, Dyskenesia". [3]

**Complementary Exams:** So-called "complementary" examinations such as medical imaging can complement this diagnostic approach.

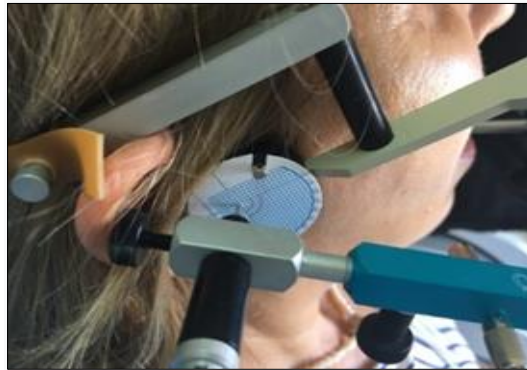#### Imaging:

Different techniques can be used to explore ATM. CT tomography; scanner, Cone Beam and MRI. The acquisition of medical imaging allows a more or less accurate detection of dysfunctions, each of them makes it possible to highlight that the contralateral bone structures of the MRI that can visualize and structures bones and soft structures of the ATM: the gold standard (Fig. 5) [4, 5].



**Fig. 5: The difference between different imaging techniques represented by a banana**


Unfortunately, we can't address our patients for MRI of the ATM, in medical terms patients are more important for magnetic resonance examinations, which is why we exploit the advantages of mechanical axiography such as the Quick axis of the firm FAG (Fig. 6) [6].




**Fig. 6: Axiography mounted on patient**

#### **Axiography:**

Mack and Slavicek were the first to have created an extraoral device materializing condylar and mandibular kinematics. Since its use has become rational in aids to diagnosis of TMJ. The apparatus consists of two arches mounted parallel in the frontal plane, an occlusal fork inserted on the mandibular arch and previously loaded with a polyvinyl siloxane impression material. A sagittal arch recording arm on which the record pen and the drum stand next to right and left para-condylar flags. The recording stylus is fixed on the locator arm in contact with the corresponding recording area at the intersection of the two horizontal and frontal axes, thus materializing the arbitrary hinge axis: this is the point '0'. The patient is asked to perform opening and closing movements by previously inserting carbon paper between the recording pen and the para-condylar flag. Thanks to the analysis of the para-condylar recording ranges of axiographic recordings: direct perception of the amplitude, the shape, the possible rupture of the condylar path has largely facilitated the establishment of the positive diagnosis and thereafter the therapeutic decision in relation to each clinical case so we saw the creation of a standard mapping of the patients of our service. Interposed with that established by Dupas in 1992, the correspondence was perfect despite that there is an infinity of axiographic trace (Fig. 7) [7]. This superposition concerns the shape and angulation of plots recorded on the para-condylar flags.



**Fig. 7: Cartography of axiographic plots**



**Fig. 8: Example of superposition between two axiographic recordings (that of Dupas on the left and ours on the right)**




Typical axiographic traces corresponded to: [6]

1. Disc displacement with reduction
2. Acute Irreducible disc displacement
3. Chronic Irreducible disc displacement
4. Muscular Incoordination

### 1- Disc Displacement with Reduction:

The axiographic tracing is characterized by an articulated jump upwards during the mouth opening movement or down during the closing movement, this articulated jump can be early, late or in the middle of the path synonymous with the condyle mandibular could catch up with his joint disc during mandibular kinematics.


The prognosis is favorable especially if the jump of joint is precocious.



**Fig. 9: Plot of a reducible disc displacement with a click of go and return.**

### 2- Acute Irreducible Disc Displacement:


The axiographic examination shows a short straight line associated with overlays (Fig. 10).



**Fig. 10: Plot of an acute irreducible disc displacement**

### 3- Chronic Irreducible Disc Displacement:

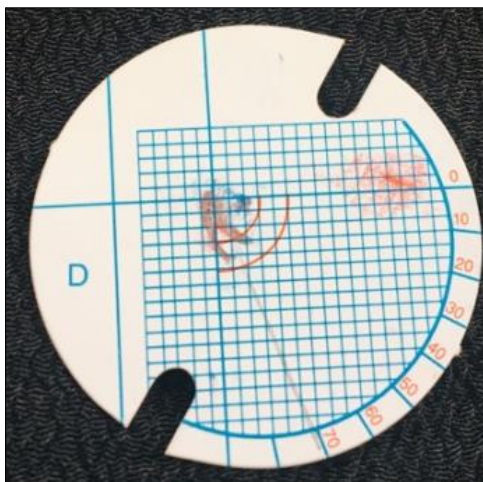
The axiographic plot may be similar to the physiological one except that the concavity, which tends to disappear, in this case the value of the angle of the condylar slope tends to decrease (Fig. 11).



**Fig. 11: Plot of a chronic irreducible disc displacement**

#### 4-Muscular Incoordination:

The plot is often split and overloaded with small jerky movements synonymous with ligamentous distortion (Fig. 12).



**Fig. 12: Tracing a muscular incoordination**

Therapeutic management: [8-10]

We start by changing the behavior with common sense tips like not cracking in apples, sandwiches, avoiding yawning and adopting a good postural position during the day and night.

Restoration of functional occlusal curves following precise occlusal analysis on semi-adaptable articulator. It is done by two methods: additive to the composite and subtractive by selective grinding → freedom of functional movements.

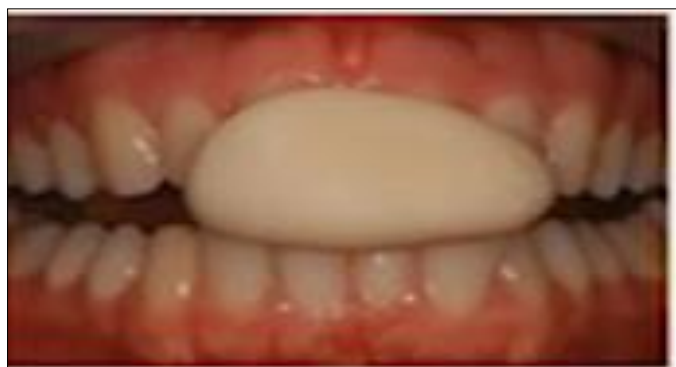Restore edentulousness when it exists to optimally ensure the three occlusal functions: mandibular guidance and centering.

Sometimes we have to move to the port of occlusal splint, three types of splints are proposed in the scientific literature and whose effectiveness has been proven by many works such as those of: Carlier and Ré (2009), Dupas (2005), Laplanche (2010).

#### Three types of occlusal splint exist:

##### **BOA (Anterior occlusal abutment):**

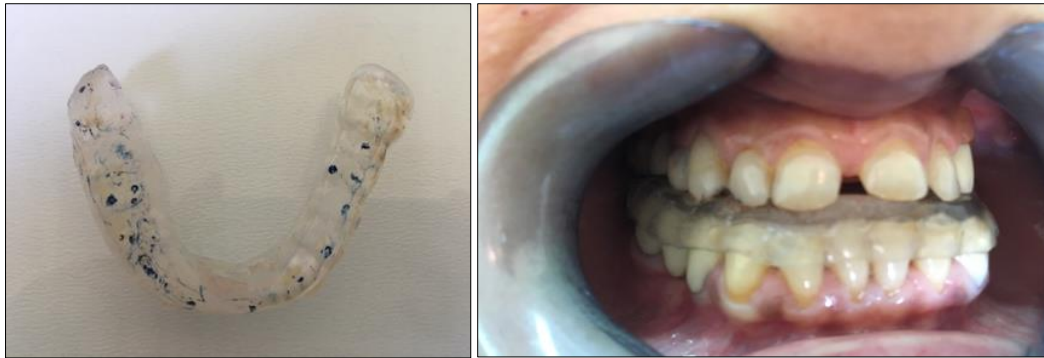Short-term emergency treatment (five days) in case of acute muscular symptomatology, performed extemporaneously in the dental office using photopolymerizable resin, the wearing will be continuous with the exception of meals.



**Fig. 13: Anterior occlusal abutment**

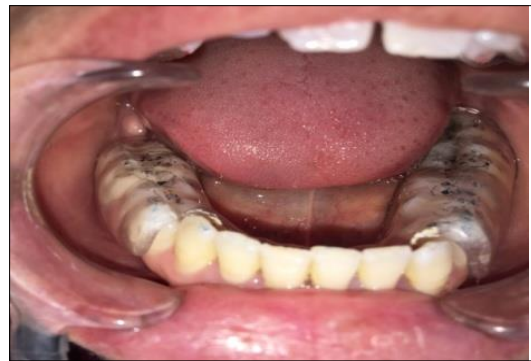#### **Occlusal Splint Muscle Reconditioning:**

It is made on articulator semi adaptable to the real settings (condylar slope, angle of Bennet) and in centered relation ensuring a good functional former guide and balanced posterior contacts, indicated in case of chronic musculo-articular symptomatology. Its port is nocturnal for a few weeks (Fig. 14).



**Fig. 14: a-b Muscle reconditioning occlusal splint principle and clinical realization**

Prepositioning splint: It is a partial posterior occlusal splint ensuring contacts between the anterior teeth themselves, the occlusal contacts will be made on the whole of the arch, as for an occlusal gutter full recovery. Indicated in cases of irreducible conduction discomfort acute and chronic The GAP is formally contraindicated when it is impossible, in spite of the anteposition, to obtain anterior contacts with an overlap of at least 2 mm (in this case patients with no recovery)., an anterior gap or an overhang too important) its purpose is the decompression of the posterior bilaminar zone by advancement and condylar lowering, its wearing is almost continuous (except meals) for eight to ten weeks and weaning (Fig. 15).



**Fig. 15: Partial Articular Anteposition splint**

## CONCLUSION

The problems of the temporomandibular joint are polymorphous, the origins are polyfactorial, and the treatments are multidisciplinary.

## REFERENCES

1. Jean Paul Goulet and Gilles Lavigne: Understanding and Treating Temporomandibular Problems: Le Médecin du Québec, Volume 39, Number 7, July 2004
2. Reneau Perrine. Thesis University of Nantes: Disc displacement of ATM. Place of the dental surgeon in the therapeutic care. 2004 N ° 36
3. IASP. Orofacial Bread. Fact Shetts J. Spetember 2016
4. Hedi Romdane, Carlos Madrid. Exploration in magnetic resonance imaging of the temporomandibular joints. Oral medicine VOL. 8, No. 1 2002
5. Audrey C. Differential diagnosis of oro-facia pain. J AO NEWS # 020. Sept 2018
6. Dupas Pierre Hubert. Cranio-mandibular dysfunction: how to diagnose and treat it? CDP 2011 edition.
7. Pierre Hubert Dupas. New approach to cranio-mandibular dysfunction to diagnose occlusal gutter? CDP 2005 edition.
8. Jules E. Lemay. Temporo-Mandibular Disorders: Focus on Diagnostic Methods and Treatments. December 2012
9. Orthlieb. JD, A Giraudeau, M Jeany, J.P Re. Management of temporomandibular dysfunctions. Marseille, August 2017
10. Orthlieb. JD. DTM and occlusal orthosis. Dental information n ° 40 - 21 November 2018.