

## Evaluation of Treatment of Recurrent Post Hypospadias Fistula Repair with Buccal Graft

Dr. Tawfeeq Waleed Tawfeeq<sup>1</sup>, Dr. Osama Abdulkadim Radi<sup>2</sup>, Dr. Ali Laibi Zamil<sup>3\*</sup>

<sup>1</sup>F.I.B.M.S (Plastic), Consultant Plastic Surgeon, Medical City Institute, Baghdad-Iraq

<sup>2</sup>M.B.Ch.B., F.I.C.M.S., Surgical Department, Al-Sader Teaching Hospital, Misan- Iraq

<sup>3</sup>M.B.Ch.B., MRCS (Ireland), Lecturer, Surgical Department, College of Medicine, Ibn Sina University of Medical and Pharmaceutical Sciences, Iraq, Baghdad

\*Corresponding Author

Dr. Ali Laibi Zamil

Article History: | Received: 16.07.2021 | Accepted: 12.08.2021 | Published: 23.08.2021 |

**Abstract: Background:** Urethrocutaneous fistula after hypospadias surgery repair is the most common complication and remains a frustrating problem for the surgeon and the patient. The problem is exacerbated because the urethrocutaneous fistula may recur which adds more demands surgery. **Aim:** To evaluate the use of buccal mucosal patch graft for treatment of recurrent post hypospadias repair urethrocutaneous fistula. **Patients and methods:** Between January 2018 and August 2019 at Al- Shaheed Ghazi Al- Hariri Hospital in Medical City Complex in Baghdad. 10 boys with recurrent urethrocutaneous fistula were included in this study. Their age ranged between 5-12 years. All were repair using a buccal mucosal graft with dartos fascia as an interposed reinforcing layer. **Results:** Nine out of 10 patients who involve in this study showed complete healing of their fistula, with no recurrence of the fistula during 6 months follow up period postoperatively and also no donor site complication. **Conclusion:** The Oral mucosal patch graft is simple and easy procedure that can be used for treatment of recurrent urethrocutaneous fistula, it provided extragenital tissue for an area that had being fibrous from previous surgery. It shows to reduce the chance of recurrence of the urethrocutaneous fistula with minimal or no donor site morbidity.

**Keywords:** Urethrocutaneous fistula, surgery repair, treatment.

Copyright © 2021 The Author(s): This is an open-access article distributed under the terms of the Creative Commons Attribution 4.0 International License (CC BY-NC 4.0) which permits unrestricted use, distribution, and reproduction in any medium for non-commercial use provided the original author and source are credited.

### INTRODUCTION

Hypospadias is the comments congenital abnormality of the penis. It occurs in around 1 in every 250-male birth, with a degree of geographical variation. In western countries the incidence of hypospadias has been noticed to increase over the past 15 years. Some of difference in prevalence reported between countries and over time are artifacts of study methodology [1].

Hypospadias is a defect that occurs from an abnormality in development of urethral plate. Proximal hypospadias 25% developed as a result of failure of tabularization of the urethral plate at 11<sup>th</sup> weeks of fetal development, whereas the more common glandular hypospadias 75% are due to abnormal development of the distal fetal urethra at 16<sup>th</sup> weeks [2].

The wide spectrum of hypospadias anomalies and the many options available for hypospadias

reconstruction continue to challenge the urological, pediatric surgical and plastic surgeon [3]. One of the most common complication of hypospadias repair is urethrocutaneous fistula, with reported incidence of 4-25%, the incidence is varying in severity of hypospadias, surgical techniques and with experience of the operating surgeon [4, 5].

The incidence of fistula formation had decrease gradually in the past two decades. In 1973 Horton and Devin Estimate the incidence of fistula formation following hypospadias surgery to range between 15%-45%. In 1984, Shapira found a urethral fistula rate of 6.25% (11 cases) in series of 176 hypospadias repair including the MAGPI, flip-flap, island and free graft technique. Now days the incidence of urethrocutaneous fistula can be used to judge the success of hypospadias repair. Some procedures are more prone to fistula formation than others, for example

**Citation:** Tawfeeq Waleed Tawfeeq *et al* (2021). Evaluation of Treatment of Recurrent Post Hypospadias Fistula Repair with Buccal Graft, *SAR J Surg*, 2(4), 32-38.

fistula rate in MAGPI 0.5%-10%, whereas free graft tube repair 15%-50% [11].

## AIM OF STUDY

To evaluate using of buccal mucosal patch for treatment of recurrent post hypospadias repair urethrocutaneous fistula.

## PATIENT & METHODS

A prospective study was done between January 2018 to August 2019 at Al Shaheed Ghazi Al- Hariri hospital at Baghdad Medical City complex, involving 10 patients who were presented to us with post hypospadias repair with recurrent urethrocutaneous fistula. Patients ages were ranging between 5-12 years. All patients were subjected to surgical repair using a buccal mucosal graft. The patient's data are shown in a Table (1) below:

**Table 1: Patients Data**

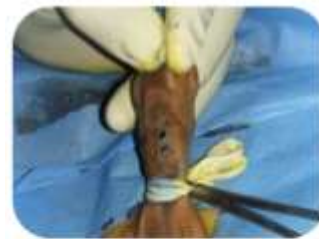Patient no.	Age (years)	Type of previous hypospadias repair	Size of fistula (mm)	Numbers of fistula	Numbers of previous surgical repair of fistula
1	5	Multistage repair with skin graft	4	1	2
2	5	Multistage repair with skin graft	4.5	1	2
3	5.6	Tabularized incised urethroplasty	5	1	1
4	7	Multistage repair with skin graft	3.5	1	1
5	6	Unknown	4	1	1
6	5	Tabularized incised urethroplasty	4.6	1	2
7	8	Multistage repair with skin graft	5	1	2
8	9	Multistage repair with skin graft	3.7, 2.5	2	1
9	6	Multistage repair with skin graft	5, 4.5	2	1
10	12	Unknown	6	1	3

All operations were done at least one year from last failed post hypospadias fistula repair. Preoperative assessment was done to assess the size, site, and number of fistulae together with assessment of pliability of surrounded soft tissue. The routine preoperative investigation was sent to all of our patients, including hemoglobin level, bleeding profile and virology screen. Preoperative informed consent was taken from all of our patient's parents.

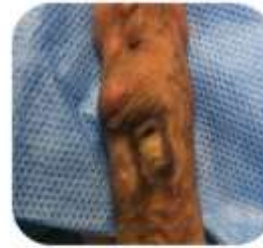## Surgical Technique

All operations were done under general anesthesia, the operation began by measuring the size of the fistula and apply glans skin traction 3/0 silk suture after that methylene blue is injected in the urethra, to ensure the site and the number of fistulae, then urethral dilatation is done. All of our operations were done using tourniquet that warps around the root of the penis which is released every 20 minutes. A suitable size silicone catheter then inserted, by using methylene blue, the circumferential incision is marked around the fistula (fistulas), then by using a number 15 scalpel, circumferential incision is done around fistula. This incision is deepened gradually, then with using fine blunt end scissors, the fistula dissected free from its surrounded tissue down to the urethral wall. In area

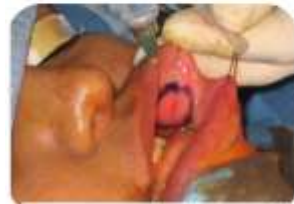where the 2 fistula are too near to each other, the tissue bridge between them is incised to convert them to single fistula, after finishing release of fistula, the size is measure again, then the donor site is prepared on buccal mucosa were two traction silk are applied to the corner of the mouth and with assistant pull them, we injected Xylocaine 2% with 1:200000 adrenaline to donor site, caution is practice to stay below Stenson's duct. Buccal mucosal graft is harvested according to the size of the defect, harvesting done by incised the mucosal graft circumferentially, then undermined by scissor and raised it from its bed. The buccal mucosal graft then defeated and the donor site is closed by using (3/0) polyglactin interrupted suture. The buccal mucosal graft sutured to the defect using (6/0) polyglactin inverted interrupted suture that ensures adequate contact to the buccal mucosal graft to the urethral epithelium. Adequate dartos fascia then dissected from nearby adjacent tissue and moved without tension (some time required complete degloving to penis to ensure release dartos without tension) and used to cover the buccal mucosal graft as protective intermediate layer and suture. After securing adequate hemostasis, skin suture using (6/0) polyglactin interrupted sutures, no drain was used in all of our cases As in figure (4).



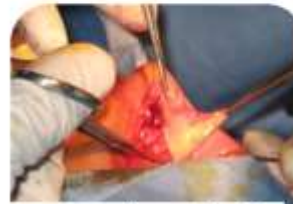Methylene blue is injected in urethra to ensure the site and the number of fistulae



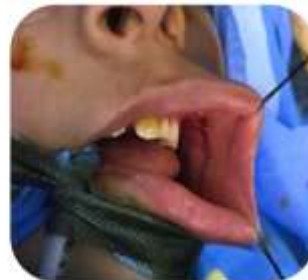By using methylene blue, the circumferential incision is marked around the fistula (fistulas)



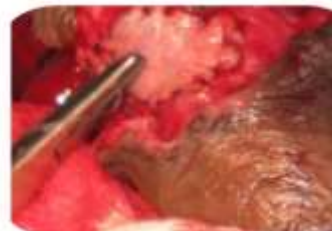Donor site is prepared for harvesting of graft



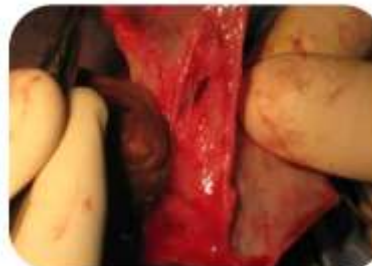Buccal mucosal graft is harvested according to size of the defect



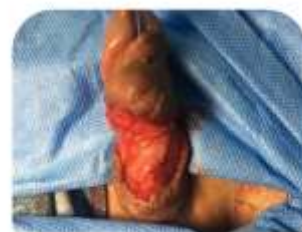donor site is closed by using (3/0) polyglactin interrupted suture



The graft sutured to the defect using (6/0) polyglactin inverted interrupted suture



Adequate dartos fascia then dissected from adjacent tissue and moved without tension used to cover the graft



Dartos suture using (6/0) polyglactin interrupted suture, no drain was used



Skin suture using (6/0) polyglactin interrupted suture

**Figure 4: Steps of surgical techniques**

Dressing then done by using antibiotic impregnated gauze that wrapped around the penis, and second layer of dressing is used by using Betadine

impregnated gauze, then dry gauze is applied as the third layer. The dressing then secured to its position using adhesive medical plaster. Patients were kept in

hospital for at least one day postoperatively and then discharged on the next day after changing their dressing to ensure there is no skin congestion or hematoma. All of our patients were kept on injectable 3<sup>rd</sup>. generation cephalosporine for 2 days postoperatively, then continue on oral antibiotics until the time of removal of a catheter which was usually done 10 days postoperatively. All of our patients were kept under observation and follow up at least 6 months postoperatively. During follow up period any sign of fistula recurrence was observed, i.e. urine dripping during micturition or splashing also difficulty in micturition or any torsion of penis was also observed.

Donor site morbidity like pain, scar, numbness also being evaluated during follow up period. All of our patients were kept on daily calibration using a medical thermometer.

## RESULTS

Ten male patients presented to us with history of recurrent post hypospadias urethrocutaneous fistula. fistula size was ranging between (3.5 – 6) mm. number of fistulas was 1 in 8 patients and 2 in 2 patients. Site of fistula: 2 coronal, 4 distal shaft, 1 midshaft, 3 penoscrotal as following in figure (5):

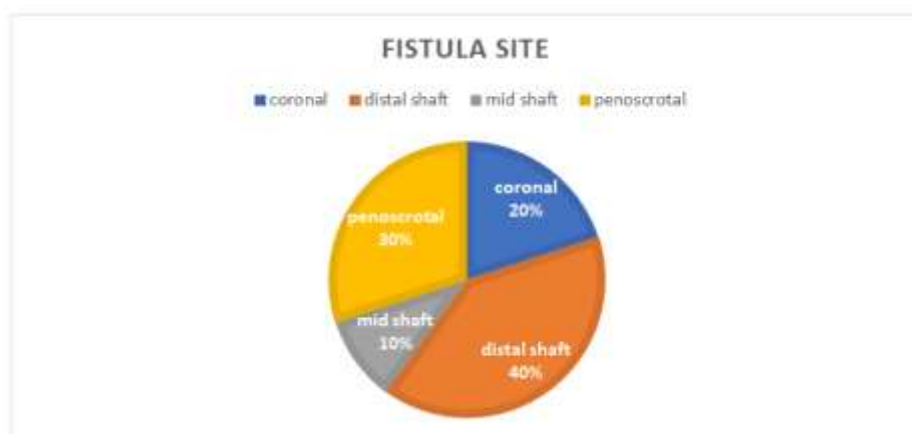

Figure 5: Fistula Site

All of our patients had previous failed urethrocutaneous fistula repair, with 5 patients had 1 previous failed operation, 4 patients had 2 previous

failed operations and 1 patient had 3 previous failed operation.as show in Figure (6).

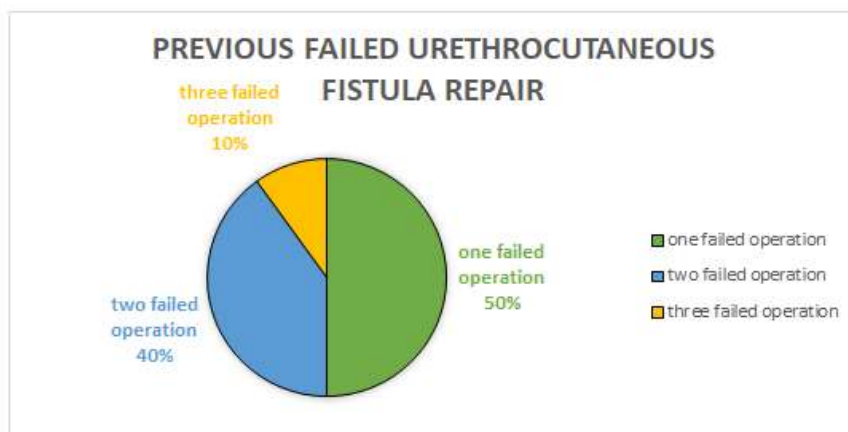


Figure 6: Previous Failed Urethrocutaneous Fistula Repair

Nine out of 10 patient who involve in this study showed complete healing of their fistula, with no recurrence of the fistula during follow up period. Those

patients had a good straight urine stream with no penile torsion during follow up period 6 months, as in figure (7) & (8).



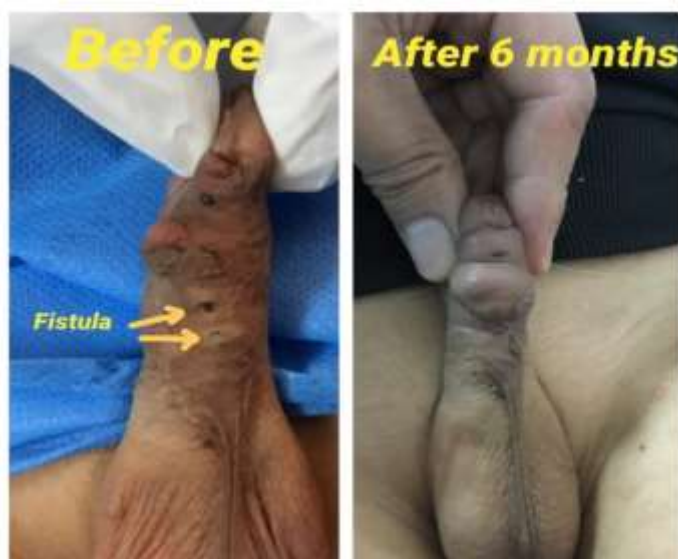

Figure 7: Pre & Post Fistula Repair case 1

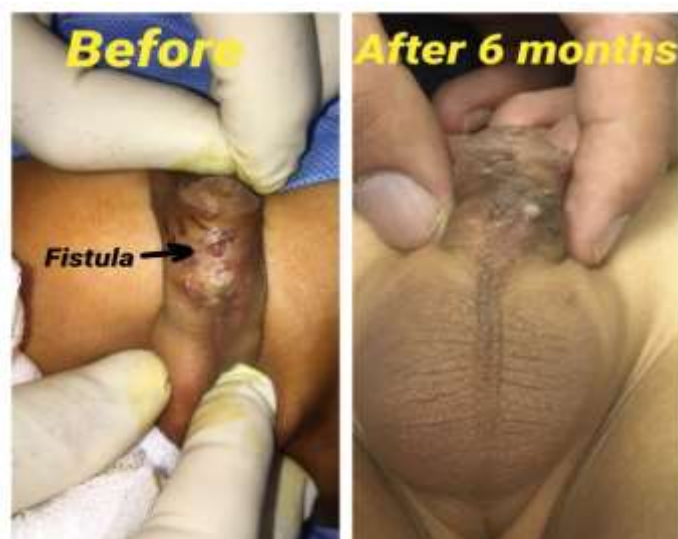

Figure 8: Pre & Post Fistula Repair case 2

Only one of our patients (number 9 who had 2 fistula) had recurrence of fistula (one fistula), and size of fistula was smaller than its size preoperatively (5mm versus 2mm). This patient had postoperative catheter obstruction and was scheduled for another operation later one.

In all of our patients had no postoperative complication noticed as wound infection, dehiscence, hematoma also, all our patients had no donor site complaining like infection, numbness, cheek hematoma or scarring.

## DISCUSSION

One of the most frustrating and disappointed complicating that could be encountered after hypospadias surgery is the urethrocutaneous fistula. Urethrocutaneous fistula post hypospadias repair remains the most common problem that could be occurred even in the hands of experienced surgeon, however, with

steadily improving in surgical techniques and tissue handling, this complication is diminished [8, 13, 14].

One of the challenging problems is dealing with recurrence enterocutaneous fistula with a paucity of local tissue, which is precluded using of local tissue for adequate covering of fistula. In present of healthy, good, and adequate penile skin, the fistula can be closed simply, but this not in the case of recurrent urethrocutaneous fistula, for these cases where the local tissue is scary and cannot be used for management of urethrocutaneous fistula, extragenital tissue had been used, namely buccal mucosal graft [12, 15, 16].

In this study buccal mucosal graft was used successfully for treatment of recurrent post hypospadias fistula, where 9 out of 10 patients whom involved in this study achieved satisfactory result in the management of their urethrocutaneous fistula in term of absent of the recurrent fistula during follow up period

with straight urine stream and absent of donor site morbidity. All of our patient whom involve in this study had previous failed operation for treatment of fistula, and the surrounding area lack pliability and supple soft tissue that precluded us to use same surrounding tissue to close the fistula. Thus, buccal mucosal graft was the salvage procedure for such patient. Fistula repair by using buccal mucosal graft was successful in every site of shaft of penis and we noticed no difference in successfulness of using of buccal mucosal graft at any site of penis. One of critical area of healing in reconstruction of urethra which was noticed by other authors is the coronal area, since it relatively had low vascularity and regarded transition zone that located between penile skin and glands [17], even so in our study, mucosal patch graft which was used in coronal area (2 cases) had achieved good healing with no recurrence of fistula in such area was recorded.

One of the factors which may contribute to fistula recurrence is suture line overlapping, so that multilayered fistula repair by using interposition well vascularized tissue is recommended to prevent fistula in primary hypospadias repair and also prevent fistula recurrence. Dartos fascia had wide application as reinforcement interposing layer that used in fistula repair [18, 19]. In this study, dartos was used successfully to covered the mucosal patch graft and act as interposing barrier layer to prevent suture overlapping. Despite dartos layer has been previously harvested for previous fistula repaired, we found in our study, Sufficient and adequate vascularized dartos layer that can be mobilized from opposite site from below the skin flap and used to cover the mucosal patch graft without any tension or creating of penile torsion.

Our study is consistence with Jalil Hosseini *et al.*, [12], were they used buccal mucosal graft in 14 children whom had post hypospadias urethrocutaneous fistula, fistula repaired in this study was used in 6 patient who had previously failed fistula repair and other patient 8 patient was used as primary procedure for fistula repair, their result showed that fistula repair using mucosal patch graft was successful in 11 out of 14 patient (78.6%), and in those children, where they have a fistula recurrence after using buccal mucosal patch, the diameter of fistula was smaller than before the operation.

Buccal mucosal patch graft also being used for treatment of recurrent large urethrocutaneous fistula after hypospadias repair by Andras Kiss *et al.*, [15]. in 7 patient their result show 6 out of 7 cases had successful repair with no fistula recurrence, they had only failed case in coronal region, despite this failed, there was significant decrease in size of fistula in comparing with preoperative sized (4.5 to 1 mm) which give good chance for later on closure.

Ahmed kh. Jasim [16] Also used mucosal patch graft in treatment of recurrent hypospadias

urethrocutaneous fistula in 12 patients, and his result show that 10 out of 12 cases (83.3%) had successful closure with no recurrence of fistula during follow up period.

All above mention studies show no significant donor site morbidity like pain, scarring or damage to buccinator bundles and Stenson's duct, this is attributed to small patch of mucosa that being harvest away from Stenson's duct.

Hamby in 1941 declared of the possibility of using buccal and bladder mucosal patch graft for urethral reconstruction, during Hamby period there was a high risk of infection (pre antibiotics area), this problem makes Hamby to use bladder mucosa. However, buccal mucosal graft which is used nowadays instead of bladder mucosa for urethral reconstruction and fistula repair had several advantages over bladder mucosa, it avoids an abnormal scar that used for cystotomy, also bladder mucosa had inherent complication such as urethral hyperplasia, graft eversion, prolapse and distal obstruction [20, 21].

Buccal mucosal graft because of its histological characteristic is regarded to have optimal vascular characteristic that can be used for reconstruction of urethra. Buccal mucosa had thick epithelial layer and thin lamina propria, this make the buccal mucosa graft mechanically stiff and in the same time easily to be handle, also buccal mucosal graft is extremely elastic and show low tendency to be contracted. The relatively thin lamina propria of buccal mucosa graft allow adequate transfer of nutrition by diffusion (imbibition) from recipient site and this together with extensive vascularity of lamina propria which allow new capillary to grow into graft (inosculation), these two criteria of lamina propria of the buccal mucosa graft i.e. thin and well vascularized will ensure adequate intake of urethrocutaneous fistula. Also, buccal mucosal graft had natural inherent barrier to risk of local sepsis [9, 16, 22].

In this study oral mucosal graft had being harvest from inner cheek rather than from lip, cheek harvesting mucosa is preferable than that of the lip because the mucosa of the cheek is thicker and more robust than the mucosa of the lip. Also, the width of the lip limits the size of the graft, also less early and late complication when compared with lip harvesting mucosa graft. One of the devastating complication after mucosa graft harvesting from lower lip is lip contracture which is reported to be occurred in (3-5%) of patient after mucosal patch graft harvest from lower lip. Some authors recommended that cheek wound remain open after graft harvesting and allow to heal by secondary intention to reduce pain and tightness [10], however we didn't found that closure of donor site lead to problem to patient, and both pain and tightness is not regarded as big problem to patient, and of most our

patient can tolerated it with gradual improving of symptoms within 5 days post operatively.

Some authors recommended to used tunica vaginalis flap for treatment of recurrent urethrocutaneous fistula after hypospadias. However, this procedure is associated with some complication like scrotal hematoma, abscess, and even penile tourniquet [22].

## CONCLUSION AND RECOMMENDATIONS

Oral mucosal patch graft is simple and easy procedure that can be used for treatment of recurrence urethrocutaneous fistula after hypospadias repair, it provided extragenital tissue for area that had being scared and fibrous from previous surgery. It shows to reduce the chance of recurrence of urethrocutaneous fistula with minimal or no donor site morbidity.

We recommended buccal mucosal patch graft for treatment of recurrent urethrocutaneous fistula post hypospadias repair.

## REFERENCE

- Farhadieh, R., Bulstrode, N., & Cugno, S., editors. (2015). Plastic and Reconstructive Surgery: Approaches and Techniques. John Wiley & Sons, Ltd., U.K., pp.588, 589.
- McCarthy, J. G., Galiano, R. D., & Boutros, S. G. (2006). Current therapy in plastic surgery. Elsevier Inc, Philadelphia; pp. 425.
- Mania Lima, Gianantonio Manzoni. Pediatric Urology, 1<sup>st</sup> ed., springer, 2015; pp. 259.
- Belman, A. B. (1994). The de-epithelialized flap and its influence on hypospadias repair. *The Journal of urology*, 152, 2332-2334.
- Dodson, J. L., Baird, A. D., Baker, L. A., Docimo, S. G., & Mathews, R. I. (2007). Outcomes of delayed hypospadias repair: implications for decision making. *The Journal of urology*, 178(1), 278-281.
- Thomas, D. F., Duffy, P. G., & Rickwood, A. M., editors. (2008). Essentials of paediatric urology. Informa Health Care, U.K., pp.214.
- Gearhart, J. P. editor. (2003). Pediatric urology. 1<sup>st</sup> ed., Humana Press, New Jersey, U.S.A., pp.105, 121.
- Poppas, D. P., & Retik, A. B., editors. (2003). Atlas of clinical urology. vol. 4 pediatric urology, 1<sup>st</sup> ed., springer, New York. pp.59, 69.
- Brandes, S. B., & Morey, A. F. editors. (2014). Advanced male urethral and genital reconstructive surgery, 2<sup>nd</sup> ed., Humana press, pp.25, 26, 18, 312.
- Azmy, A. A., & Hadidi, A. T. (2004). Hypospadias surgery: an illustrated guide. Springer; pp.277, 279, 281.
- Hosseini J, Kaviani A, Mohammad hosseini M, Rezaei A, Rezaei I, Javanmard B. Fistula repair after hypospadias surgery using buccal mucosal graft. *Urology journal*. 2009 ;6(1):19-22.
- Gupta, V., & Sharma, S. B. (2006). Use of facia lata graft blanket wrap to prevent fistulas in hypospadias repair. *Journal of Indian Association of Pediatric Surgeons*, 11(2), 89-91.
- Srivastava, R. K., Tandale, M. S., Panse, N., Gupta, A., & Sahane, P. (2011). Management of urethrocutaneous fistula after hypospadias surgery– An experience of thirty-five cases. *Indian journal of plastic surgery: official publication of the Association of Plastic Surgeons of India*, 44(1), 98-103.
- Kiss, A., Pirót, L., Karsza, L., & Merksz, M. (2004). Use of buccal mucosa patch graft for recurrent large urethrocutaneous fistula after hypospadias repair. *Urologia internationalis*, 72(4), 329-331.
- Ahmed, K. J. (2015). Outcome of Buccal Mucosal Patch Graft in the Management of Recurrent Hypospadias Urethrocutaneous fistula, *J fac med Baghdad*, 57(1), 27-30.
- Yerkes, E. B., Adams, M. C., Miller, D. A., & Brock, J. W. (1999). Coronal cuff: a problem site for buccal mucosal grafts. *The Journal of urology*, 162(4), 1442-1444.
- Jamal, Y. S., Kurdi, M. O., & Moshref, S. S. (2010). Management of Small Urethrocutaneous Fistula by Tight Ligation with Fulguration of the External Epithelium of the Tract. *Annals of pediatric surgery*, 6(3-4), 150-153.
- Neilson, A. G., & Nicholls, G. (2013). Repair of hypospadias fistula using a penile skin advancement flap with penile dartos interposition. *Journal of pediatric urology*, 9(6), 890-894.
- Sahin, C., & Seyhan, T. (2003). Use of buccal mucosal grafts in hypospadias-crippled adult patients. *Annals of plastic surgery*, 50(4), 382-386.
- Frank, J. D., Gearhart, J. P., & Snyder, H. M., editors. (2002). Operative pediatric urology, 2<sup>nd</sup> ed., Churchill Livingstone, London, pp. 171.
- Jain, M., Madeshiya, S., & Sharma, N. (2018). Single stage repair with buccal mucosal graft in hypospadias cripple patients. *International Surgery Journal*, 5(10), 3239-3245.
- Routh, J. C., Wolpert, J. J., & Reinberg, Y. (2008). Tunneled tunica vaginalis flap for recurrent urethrocutaneous fistulae. *Advances in urology*, 2008, 1-3.