

An Emergency and Challenging Life-Saving Surgery in a Newborn with Imperforate Anus in a Remote Village in South Sudan – A Case Report

Dr. Pushkar Mendiratta^{1*}, Dr. Pratyush Chandra Madhur¹, Dr. Rabi Narayan Hota¹

¹Indian Field Hospital Level II, Malakal, South Sudan

*Corresponding Author: Dr. Pushkar Mendiratta
Indian Field Hospital Level II, Malakal, South Sudan

Article History: | Received: 12.11.2023 | Accepted: 23.12.2023 | Published: 30.12.2023 |

Abstract: Anorectal malformation, a congenital defect is usually detected at birth and managed by a multispecialty team in a tertiary care hospital. We present a case of a five day old neonate, born in a remote village in South Sudan, who presented in a critical condition to our field hospital and was managed with basic resources. A 5 day old neonate was detected with imperforate anus and presented to our hospital on day 5 with abdominal distension, severe dehydration, tachycardia and tachypnoea. Radiographic investigations revealed findings suggestive of a high ano-rectal malformation. The neonate underwent an emergency exploratory Laparotomy with diversion double barrel Colostomy in a set up catering for adult combatants. The neonate gradually improved before developing burst abdomen managed with emergency wound closure. The neonate gradually accepted breast feeds and was discharged for subsequent need for definitive surgery. This was a challenging surgery with respect to the resources available at a field hospital catering to adult combatants.

Keywords: Anorectal malformations, Colostomy, Abdominal radiography, Imperforate anus, Case report.

Copyright © 2023 The Author(s): This is an open-access article distributed under the terms of the Creative Commons Attribution 4.0 International License (CC BY-NC 4.0) which permits unrestricted use, distribution, and reproduction in any medium for non-commercial use provided the original author and source are credited.

INTRODUCTION

Anorectal malformations (ARMs) incorporate a spectrum of congenital defects, with a reported incidence between 1 in 2000 to 1 in 5000 live births, being slightly more common in males [1,2]. Imperforate anus, characterised by absent external anal opening usually presents with failure to pass meconium, abdominal distension, inability to tolerate feeds, vomiting, or meconium discharging through external fistulous opening, with radiology playing a vital role in diagnosing the type [3]. Surgery is guided by the type of malformation with a multidisciplinary approach in management [3,4].

We present a case of a female neonate, diagnosed with imperforate anus at birth. Being in a remote location with no access to any surgical facility, patient presented in a critical condition to our field hospital at Day 5, where she was resuscitated, stabilised and colostomy performed at our hospital, which is otherwise setup to cater for adult combatants and non-combatants. This case reports highlights the workup and management of the case with the challenges faced in

managing this patient with a basic surgical set up, rather than an advanced paediatric surgical unit, where such surgeries would have usually been performed. This manuscript was prepared following the CARE guidelines.

CASE REPORT

A 5 day old female neonate, born of full term normal vaginal, non-institutionalised delivery was detected with imperforate anus at birth and brought to our hospital with history of multiple episodes of vomiting, inability to accept feeds, persistent crying and abdominal distension (Fig 1A). Birth weight was undocumented with no relevant antenatal history. The neonate had not passed stools since birth without evidence of meconium in urine. On examination, the neonate had severe dehydration, tachycardia with a heart rate of 184 beats per minute and tachypnoea with a respiratory rate of 60 per minute. Oxygen saturation was maintained, the neonate was afebrile and weight was 3016 gm. Moro reflex and rooting reflex were present with no other obvious structural anomaly on clinical examination (Fig 1B).

Citation: Pushkar Mendiratta, Pratyush Chandra Madhur, Rabi Narayan Hota (2023). An Emergency and Challenging Life-Saving Surgery in a Newborn with Imperforate Anus in a Remote Village in South Sudan – A Case Report. *SAR J Surg*, 4(5), 69-72.

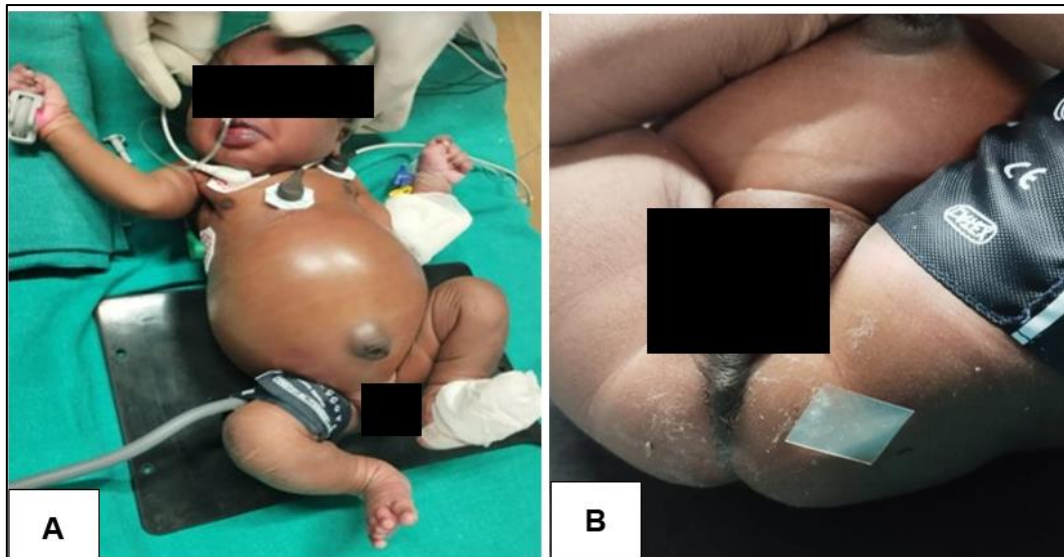

Fig 1: A. Photograph of the neonate at presentation showing abdominal distension. B. Photograph of the perineal region of the neonate with no external anal opening visualised

Urgent investigations revealed leucocytosis (15340/mm³), hyponatremia (132 mEq/L), hypokalaemia (3.0 mEq/L) and hyperbilirubinemia (12.2 mg/dl) with serum indirect bilirubin of 11.4 mg/dl. Aspartate and Alanine aminotransferase measured 48 and 82 mg/dl respectively. Haemoglobin was 22.4 mg/dl. Invertogram (Fig 2A) and prone cross table lateral view

(Fig 2B), revealed the distal rectal pouch at 5 cm from the expected anal opening and the rectal pouch above pubo-coccygeal line suggestive of a high ano-rectal malformation. Ultrasound of the abdomen and pelvis revealed no obvious intra-abdominal or pelvic congenital structural abnormality.

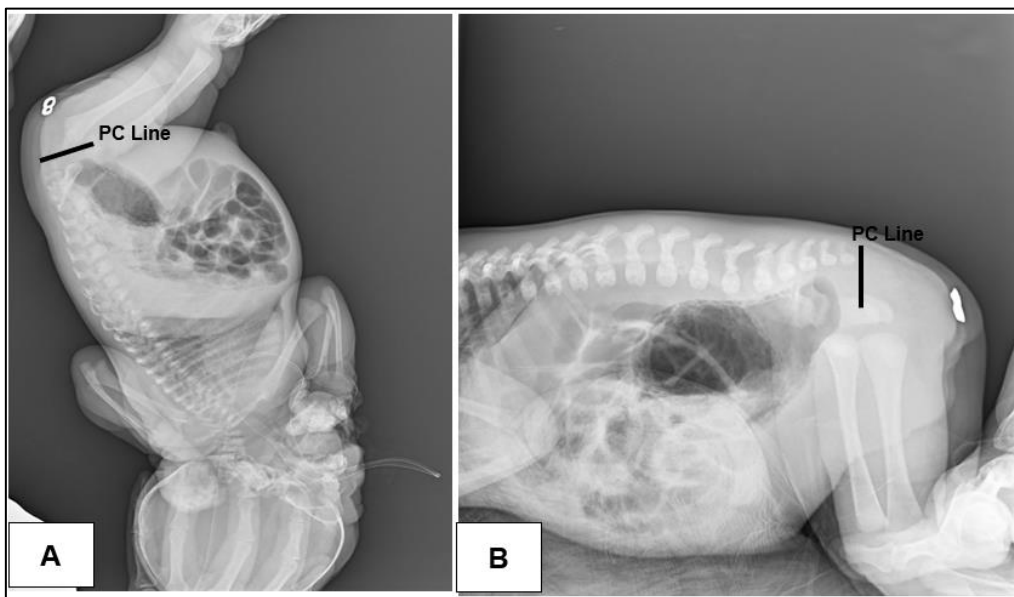


Fig 2: A. Invertogram and B. Cross table lateral view showing the distance between rectal pouch and the expected anal opening skin to be more than 1 cm and the rectal pouch above pubo-coccygeal line (PC line), signifying a high type of ano-rectal malformation

The neonate was resuscitated with intra-venous fluids and started on injectable Ceftriaxone, Metronidazole and Amikacin in the weight adjusted doses. Ryle's tube was inserted to decompress the bowel. Emergency exploratory Laparotomy was undertaken with diversion double barrel Colostomy under general

anaesthesia with endotracheal intubation. The laparotomy revealed imperforate anus with dilated small bowel and large bowel loops with intact peristalsis (Fig 3). Double barrel colostomy was placed, patient extubated on the operating table itself and shifted to the only intensive care unit available.

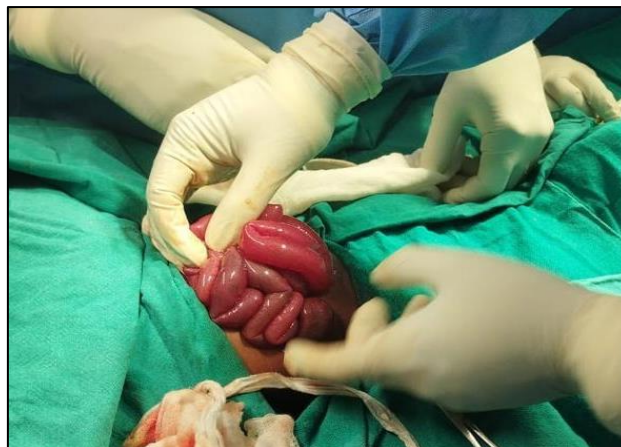

Fig 3: Intra-operative image depicting dilated but viable small bowel loops

The neonate gradually improved over next four days before developing burst abdomen on post-operative day five, which was managed with emergency wound closure. There was subsequent gradual improvement in the general condition, with the neonate accepting breast feeds on second day post wound closure. After seven days of the second surgical procedure when the neonate was tolerating breast feeds comfortably and all biochemical parameters were normal, the neonate was discharged. Instructions on colostomy care, regular follow-up and subsequent need for definitive surgery were explained to the mother. Written and informed consent was taken from the parent for inclusion of case details and images in the study.

DISCUSSION

The present case of imperforate anus presented to our hospital on day 5 with abdominal distension and severe dehydration with tachycardia, tachypnoea, and electrolyte abnormalities. Radiographic investigations confirmed a high type of ano-rectal malformation following which the neonate underwent an emergency exploratory laparotomy with diversion double barrel Colostomy. Though the neonate developed burst abdomen which was managed with emergency wound closure. The neonate was subsequently discharged.

ARMs develop due to anomalous development of hindgut with aberrations of pelvic muscles and external anal sphincter. They have been classified by Wingspread classification, classification system developed by Pena *et al.*, and by Krickenbeck classification. Anatomically, depending on the position of the blind rectal pouch in relation to the pelvic floor muscles, they are classified as high, intermediate, or low [4]. Association with multisystem anomalies, VACTREL group of anomalies and with aneuploidies is reported [5,6]. There have been documented diagnosis of ARMs antenatally, though most are detected at birth as in our case, with rare reports of delayed diagnosis [5,7]. Presence of systemic anomalies is associated with poor prognosis [8].

Radiological evaluation by Invertogram and prone cross-table lateral view is diagnostic as was done in our case. Distal rectal pouch when present at a distance of more than 1 cm from the expected anal opening or the anal dimple is suggestive of a high defect. Prone cross table lateral view overcomes the limitations of Invertogram, which may give false results due to contraction of the puborectalis sling. For complex anomalies, other investigations may be done, including contrast studies of distal colon, Cystourethrography, Magnetic Resonance Imaging [8,9].

Multi-disciplinary management is the rule, usually in a paediatric surgical unit. Such a setup if not available in the vicinity, managing such a case becomes an arduous task as happened within our setup. High type of malformations need initial diverting colostomy – usually descending or sigmoid, followed by definitive surgical repair after 4-8 weeks, while a low type ARMs usually require primary anoplasty. Posterior sagittal anorectoplasty (PSARP) described by Pena *et al.*, is the preferred surgical repair in ARMs [1,10]. Complications such as surgical site infection and wound dehiscence may occur early post-surgery, while persistent fistula and anal stenosis may occur at a later stage. Wound dehiscence which occurred in our case was repaired surgically. Complications specific to colostomy may also occur, though are usually preventable when meticulously done [1,10]. Prolonged postoperative colostomy care and protracted follow up is required in most.

CONCLUSION

Imperforate anus is a common congenital anomaly with myriad associations and is a standard surgical case in a tertiary care hospital, but the initial life-saving surgery done in our setup, with the limited resources, has not been described previously. This case also is a grim reminder of the paucity of healthcare setups in many geographical locations corresponding to the first and second delay in the three delay network in accessing surgical care. Such a case may be encountered by any medical team working in field conditions, thus providing a learning experience for everyone.

Informed Consent: Informed consent was obtained from the guardian of the patient.

Authorship: All authors attest that they meet the current ICMJE criteria for Authorship.

Acknowledgements: Nil

REFERENCES

1. Levitt, M. A., & Peña, A. (2007). Anorectal malformations. *Orphanet journal of rare diseases*, 2(1), 1-13.
2. Stoll, C., Alembik, Y., Dott, B., & Roth, M. P. (2007). Associated malformations in patients with anorectal anomalies. *European journal of medical genetics*, 50(4), 281-290.
3. Herman, R. S., & Teitelbaum, D. H. (2012). Anorectal malformations. *Clinics in perinatology*, 39(2), 403-422.
4. Holschneider, A., Hutson, J., Peña, A., Beket, E., Chatterjee, S., Coran, A., ... & Kunst, M. (2005). Preliminary report on the International Conference for the Development of Standards for the Treatment of Anorectal Malformations. *Journal of pediatric surgery*, 40(10), 1521-1526.
5. Kim, H. M., Cha, H. H., Kim, J. I., Seong, W. J., Park, S. H., & Kim, M. J. (2021). The diagnosis of an imperforate anus in female fetuses. *Yeungnam University Journal of Medicine*, 38(3), 240-244.
6. Wijers, C. H., van Rooij, I. A., Marcelis, C. L., Brunner, H. G., de Blaauw, I., & Roeleveld, N. (2014). Genetic and nongenetic etiology of nonsyndromic anorectal malformations: a systematic review. *Birth Defects Research Part C: Embryo Today: Reviews*, 102(4), 382-400.
7. Chavan, R. N., Chikkala, B., Das, C., Biswas, S., Sarkar, D. K., & Pandey, S. K. (2015). Anorectal malformation: paediatric problem presenting in adult. *Case Reports in Surgery*, 2015.
8. Thomeer, M. G., Devos, A., Lequin, M., De Graaf, N., Meeussen, C. J., Meradji, M., ... & Sloots, C. E. (2015). High resolution MRI for preoperative work-up of neonates with an anorectal malformation: a direct comparison with distal pressure colostography/fistulography. *European Radiology*, 25, 3472-3479.
9. Bischoff, A., Bealer, J., & Peña, A. (2017). Controversies in anorectal malformations. *The Lancet Child & Adolescent Health*, 1(4), 323-330.
10. Levitt, M. A., & Peña, A. (2007). Anorectal malformations. *Orphanet journal of rare diseases*, 2(1), 1-13.