SAR Journal of Surgery

Abbreviated Key Title: *SAR J Surg*
Home page: https://sarpublication.com/journal/sarjs/home
DOI: https://doi.org/10.36346/sarjs.2026.v07i06.003

ISSN 2707-7748 (P)
ISSN 2709-6912 (O)

Original Research Article

Impact of LigaSure with Normal Saline Irrigation on Recurrent Laryngeal Nerve Injury in Thyroidectomy

Saddam Ali Abbas[1]*, Ahmed Osama Hassen[1], Sinan T. Shukur[2]

[1]College of Medicine, Mustansiriyah University, Baghdad, Iraq
[2]College of Medicine, Kufa University, Najaf, Iraq

***Corresponding Author:** Saddam Ali Abbas
College of Medicine, Mustansiriyah University, Baghdad, Iraq

Article History: | Received: 17.09.2026 | Accepted: 09.11.2026 | Published: 12.11.2026 |

Abstract: ***Background***: Injury to the recurrent laryngeal nerve (RLN) is one of the most common complications during thyroidectomy. Novel surgical interventions are always necessary to decrease the incidence of such complication. ***Aim of the Study***: This study aimed to assess the protective effect of irrigation of normal saline at the anatomical site of recurrent laryngeal nerve during thyroidectomy using LigaSure. ***Methods***: This retrospective study included 100 patients admitted for different thyroid surgeries. Irrigation of normal saline at the anatomical site of RLN during surgical intervention was performed concomitantly with LigaSure. ***Results***: The current study involved 100 patients (79 females and 21 males). Most of the patients (85%) had total thyroidectomy while 10 patients had near total thyroidectomy and only five patients had lobectomy. None of the included patients reported RLN injury after one-month follow-up postoperatively. ***Conclusion*:** Irrigation of normal saline at the anatomical site of RLN during thyroidectomy revealed beneficial in decreasing rate of RLN injury.

Keywords: Thyroidectomy, Recurrent Laryngeal Nerve, LigaSure.

Copyright © 2026 The Author(s): This is an open-access article distributed under the terms of the Creative Commons Attribution **4.0 International License (CC BY-NC 4.0)** which permits unrestricted use, distribution, and reproduction in any medium for non-commercial use provided the original author and source are credited.

INTRODUCTION

Thyroid surgeries have evolved to include minimally invasive and robotic-assisted techniques, however the conventional open thyroidectomy remains the gold standard for most clinicians. Its enduring popularity stems from the unparalleled direct visualization it provides, allowing the surgeon clear access to the thyroid gland and its surrounding structures. However, this accessibility does not eliminate the inherent risks associated with the procedure, which range from minor postoperative infections to life-altering neurological or metabolic damage [1].

The most frequent complications following thyroid surgery involve the delicate balance of the neck's anatomy. Postoperative hypocalcemia—often caused by accidental trauma to the parathyroid glands—remains a common hurdle, as do bleeding and infection [2]. Yet, perhaps the most daunting challenge for any neck surgeon is the preservation of the recurrent laryngeal nerve (RLN). Tucked within the tracheoesophageal groove, the RLN is notoriously unpredictable. Its anatomical path can vary significantly, with some patients exhibiting complex branching patterns or even non-recurrent variants that defy standard expectations. Whether through excessive traction, accidental transection, or even the heat from surgical instruments, injuring this nerve can lead to devastating vocal cord dysfunction [3].

Modern surgical wisdom suggests that the most reliable way to prevent RLN injury is through meticulous, extensive dissection. Relying purely on anatomical landmarks is often viewed as insufficient given the high rate of physical variations; instead, surgeons are encouraged to visually track and expose the nerve throughout its entire course. This proactive "visual-first" approach is the primary defense against catching a hidden branch of the nerve or misidentifying a non-recurrent path during the procedure [4].

In recent years, Intraoperative Nerve Monitoring (IONM) has emerged as a critical secondary tool for enhancing surgical safety. By providing an audible and visual "real-time" check of nerve conduction, IONM allows the surgical team to verify that

the nerve is still functioning both before and after the dissection process. It is particularly indispensable in complex scenarios—such as secondary operations where scar tissue is present, or when dealing with massive goiters and invasive malignancies that shift the normal anatomy. While the consensus is that IONM should never serve as a substitute for a surgeon's trained eye, it acts as a vital safety net that can significantly lower the risk of bilateral nerve paralysis [5].

Gentle tissue handling and avoidance of excessive traction or thermal injury are also critical. The use of bipolar cautery or ultrasonic devices should be carefully controlled near the nerve to prevent heat-related damage. In cases where the nerve is adherent to tumor or fibrotic tissue, sharp dissection under magnification is preferred to minimize trauma [6].

In the current study the goal was to protective effect of irrigation of normal saline at the anatomical site of recurrent laryngeal nerve during thyroidectomy using LigaSure.

METHODS

This retrospective study included data of 100 patients admitted for thyroid surgeries in Baghdad district, in Iraq within the years 2020 to 2025. Basic patients' data including name, age, gender, residence and occupation was recorded. In addition, relevant past medical, surgical and drug history was recorded. General and local clinical examination was performed prior to patients admission.

Surgical Approach

The procedure began with the patient positioned supine, with the neck extended. A transverse incision was made along a natural skin crease, and subplatysmal flaps were elevated to reveal the strap muscles. These muscles were retracted to access the thyroid gland. Once the gland was exposed, the middle thyroid vein was identified and sealed using LigaSure with saline irrigation of the RLN position. The superior pole vessels were dissected and sealed, with attention to preserving the external branch of the superior laryngeal nerve. Inferior thyroid vessels were similarly managed, and the RLN was identified and preserved throughout the dissection. The thyroid lobes were then mobilized so as to be dissected off the trachea, with LigaSure facilitating clean separation and hemostasis. After removal, the surgical field was inspected for bleeding. Closure involved reapproximation of the strap muscles and platysma, followed by layered skin closure.

Postoperative Care

After lobectomy, all patients were observed for 6 hours and were discharged home if no complications appeared. Sub-total thyroidectomy and total thyroidectomy patients were admitted overnight, and their ionized calcium level was checked in the morning. Patients were discharged if the ionized calcium level was above g mg/dl.

Follow-Up

Post-operative follow-up consisted of an office visit 2 weeks after the operation or earlier on patient request. Post-operative larynx visualization was performed only if patients described voice or swallowing abnormalities on specific questioning. If any abnormality was detected on the first post-operative visit, such as hypocalcemia or vocal cord palsy, the patients were followed monthly for up to a year or until the abnormality resolved.

RESULTS

The current study involved 100 patients (79 females and 21 males). Patients age categories are illustrated in figure 1 while presenting diagnosis is illustrated in figure 2. Of the included patients, 40 patients had disease duration of less than 2 years while 60 patients had disease duration of 2 years or more. Most of the patients (85%) had total thyroidectomy while 10 patients had near total thyroidectomy and only five patients had lobectomy. None of the included patients reported RLN injury after one-month follow-up postoperatively.

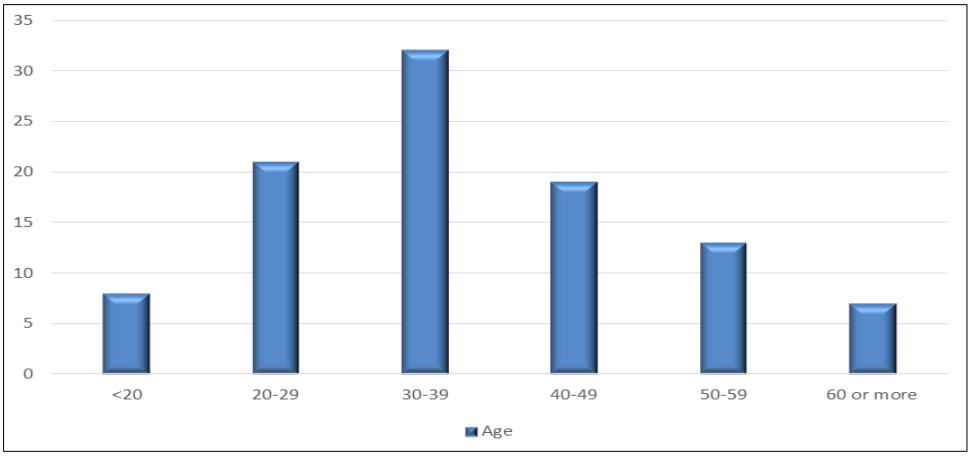

Figure 1: Patients' age categories

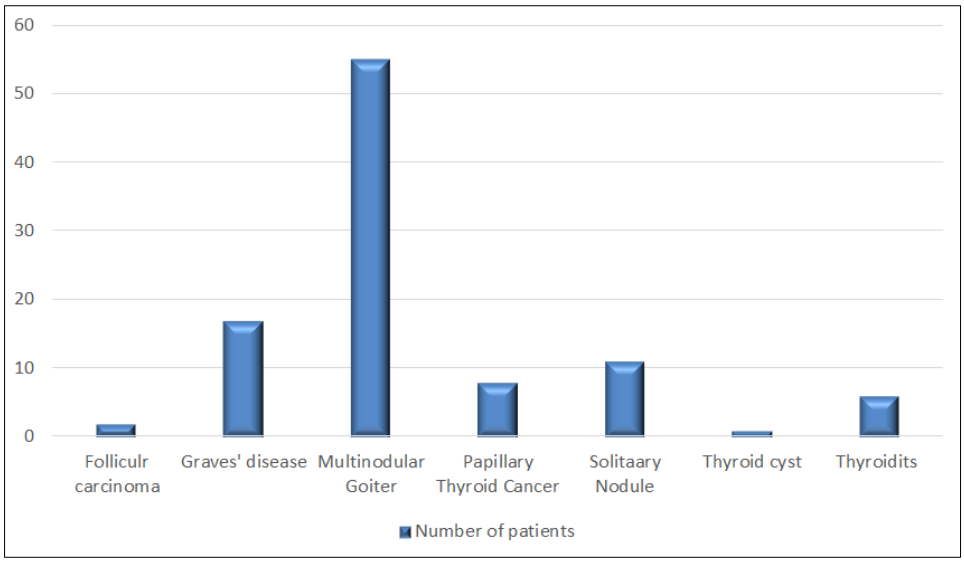

Figure 2: Patients' presenting diagnosis

DISCUSSION

Thyroidectomy, whether entire or partial, is the preferred therapeutic approach for numerous thyroid disorders, including Graves' disease, thyroid goiters, and neoplasms, and is characterized by low morbidity and death rates [7]. High morbidity in thyroid surgeries is frequently caused by injury to the surrounding structures, with hypocalcaemia and RLN paralysis among the most critical postoperative complications [8].

In the current study we evaluated the surgical outcome of irrigation of normal saline at the anatomical site of recurrent laryngeal nerve during thyroidectomy using LigaSure. This retrospective study included 100 patients admitted for either lobectomy, subtotal o total thyroidectomy. None of the included patients reported injury of RLN showing the high efficiency of our novel surgical approach.

LigaSure utilizes bipolar energy to denature collagen and elastin in vessel walls, facilitating the permanent union of vessels up to 7 mm in diameter. This approach is especially beneficial in thyroidectomy, as extensive control of bleeding and the protecting fragile structures are essential [9].

On the other hand, LigaSure generates heat during vessel sealing, which can affect adjacent tissues, therefore increasing risk of injuring the perineural tissues. This could increase susceptibility to mechanical or thermal damage to the RLN [10]. Saline irrigation during LigaSure acts as a thermal sink, absorbing excess heat, thus reduces the risk of thermal injury to the RLN.

In addition, saline irrigation during LigaSure clears blood from the surgical field, allowing better visualization of the RLN and surrounding structures. This facilitates more accurate dissection and decrease risk of nerve injury. Furthermore, saline preserves tissue hydration and prevents fragility of adjacent perineural structures.

Several previous studies report the beneficial effect of LigaSure during thyroidectomy [11, 12], on the other hand, other studies denied the benefit of LigaSure [13]. Despite that contradicting data and according to the majority of reports, LigaSure effectively decreases the frequency of RLN injury in patients admitted for thyroidectomy. However, the risk of this postoperative RLN injury is still of a much concern to thyroid surgeons. Based on our study findings, the addition of saline irrigation to LigaSure further decreases the incidence of RLN injury.

CONCLUSION

Saline irrigation with LigaSure during thyroidectomy effectively reduced the RLN injury.

REFERENCES

1. Fassari A, Gurrado A, Iossa A, Micalizzi A, Polistena A, Sibio S, Crocetti D, Bononi M, Testini M, Avenia N, Cavallaro G. Definition of learning curve for thyroidectomy: systematic review on the different approaches. Gland Surgery. 2023;12(7):989.
2. Hong PK, Pathak A, Shirali AS. Predictors of postoperative complications following thyroidectomy: a systematic review. Surgery in Practice and Science. 2024;18:100252.
3. Swain SK. Injury of Recurrent Laryngeal Nerve in Thyroid Surgery: A Scoping Review. Matrix Science Pharma. 2025;9(1):1-5.
4. Mahyoub A, Aljohani AA, Althobaiti AJ, Alharbi SS, Alahmary AA, Algarni RS, Alamoudi SK, Alshahrani MS, Alkhaldi TM, Alqubaishi AH, Marzogi10 KA. Recurrent and superior laryngeal nerve injury in thyroid surgery: literature review. International Journal of Community Medicine and Public Health. 2021;8(2):862.

5. Merchavy S, Kassem K, Awawde R, Abd Elhadi U, Safia A. Intraoperative Nerve Monitoring Parameters and Risk of Recurrent Laryngeal Nerve Injury in Thyroidectomy: A Systematic Review and Meta-Analysis. Biomedicines. 2025;13(10):2516.
6. Stefanou CK, Papathanakos G, Stefanou SK, Tepelenis K, Kitsouli A, Barbouti A, Tsoumanis P, Kanavaros P, Kitsoulis P. Surgical tips and techniques to avoid complications of thyroid surgery. Innovative Surgical Sciences. 2022;7(3-4):115-23.
7. Vouchara A, Chorti A, Tzikos G, Menni A, Ntouma S, Giza S, Tzitiridou-Chatzopoulou M, Bakkar S, Galli-Tsinopoulou A, Michalopoulos A, Papavramidis TS. Thyroidectomy in children and adolescents: a systematic review. Gland surgery. 2024;13(5):697.
8. Adinugroho P, Randy R. The Analysis Study of Management, Complication and Outcome after Thyroidectomy and Parathyroidectomy: A Comprehensive Systematic Review. The International Journal of Medical Science and Health Research. 2024;4(5):1-20.
9. Grøndal AY, Høgsbro M, Pryds K, Pedersen HB, Jacobsen H. Intra-and postoperative complications using ligasure™ small jaw in patients undergoing thyroidectomy: A register-based study. European Archives of Oto-Rhino-Laryngology. 2021 Nov;278(11):4491-500.
10. Spartalis E, Giannakodimos A, Giannakodimos I, Ziogou A, Papasilekas T, Patelis N, Schizas D, Troupis T. The role of LigaSure™ and Harmonic Scalpel in the preservation of recurrent laryngeal nerve during thyroidectomy. The Annals of The Royal College of Surgeons of England. 2022;104(5):324-9.
11. Kadhim SH, Ibrahim KM. A comparative study between the outcome of using LigaSure® versus suture ligation in thyroid surgery. Medical Journal of Babylon. 2023;20(3):569-73.
12. Habash M, Sultan A, Ghareeb O. Surgical outcomes of ligasure bipolar device versus conventional technique in total thyroidectomy. Journal of Natural Science, Biology and Medicine. 2022;13(2):119-23
13. Best CA, Hussain J, Johnson-Obaseki S. Alternative sources of cautery in thyroid surgery and the risk of recurrent laryngeal nerve injury: a retrospective, risk-adjusted analysis from the National Surgical Quality Improvement Program. Journal of Otolaryngology-Head & Neck Surgery. 2024;53:19160216241265687.